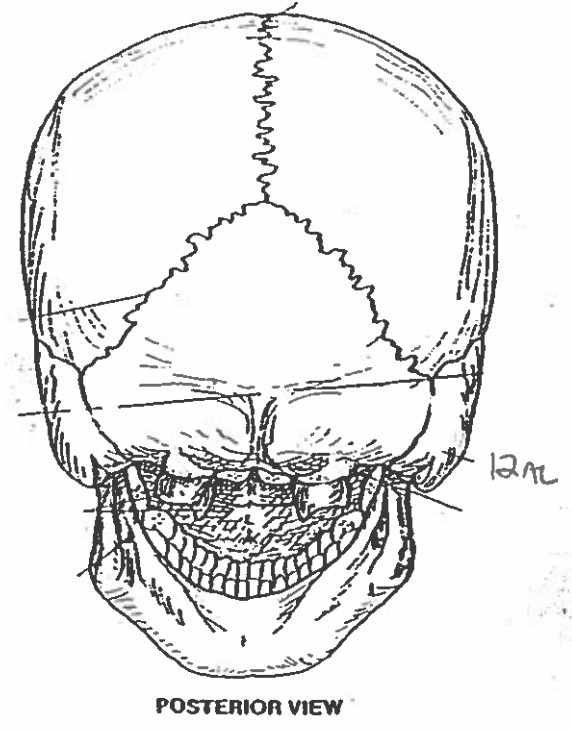
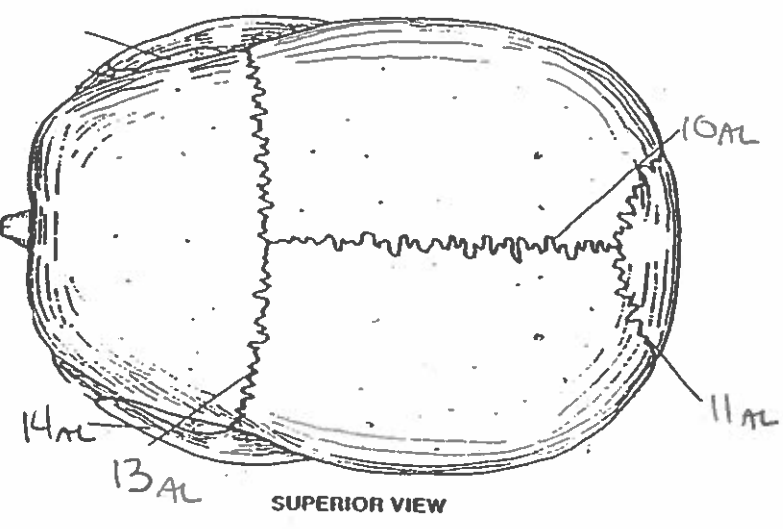
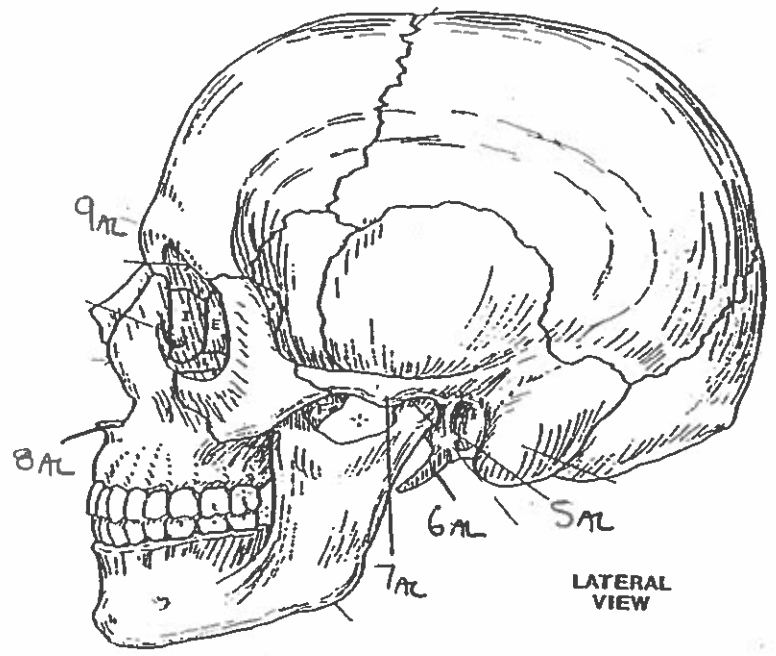
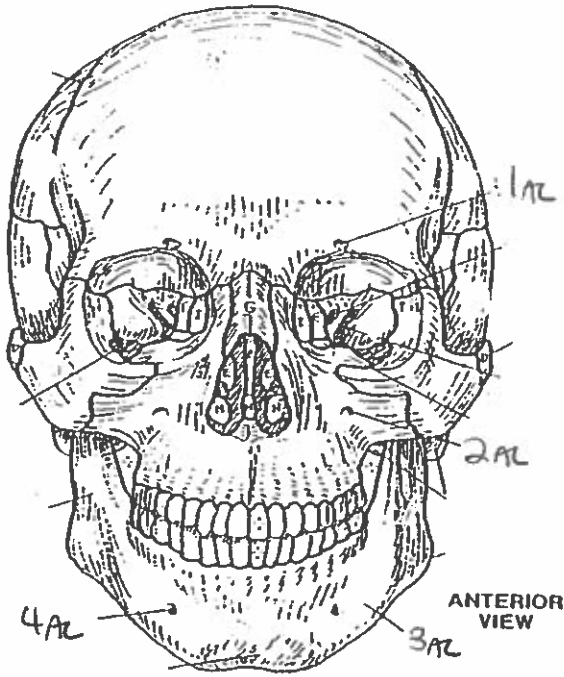
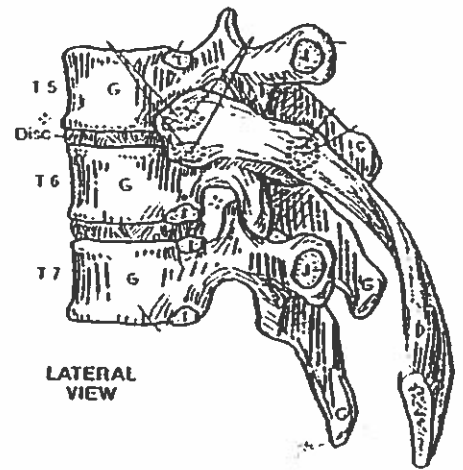
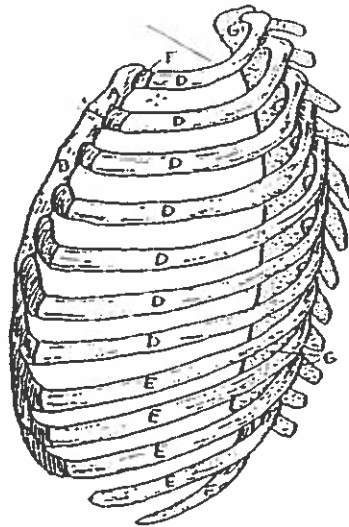

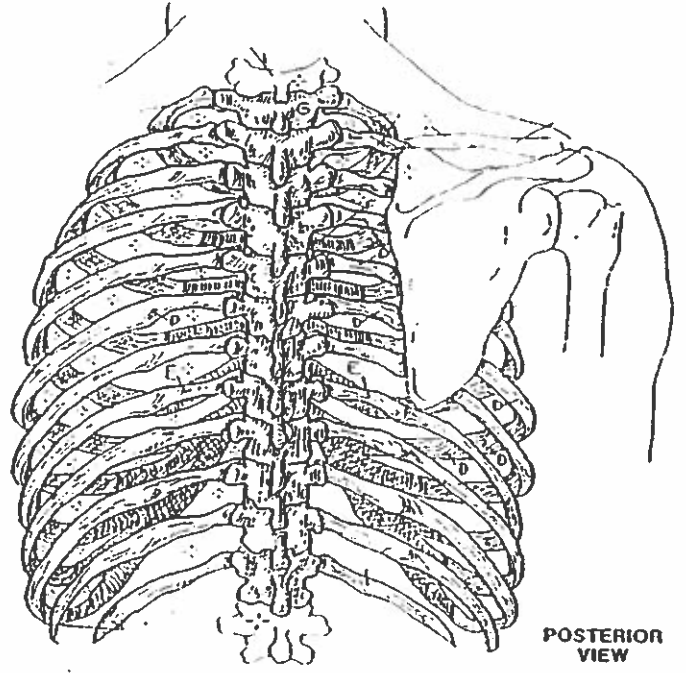
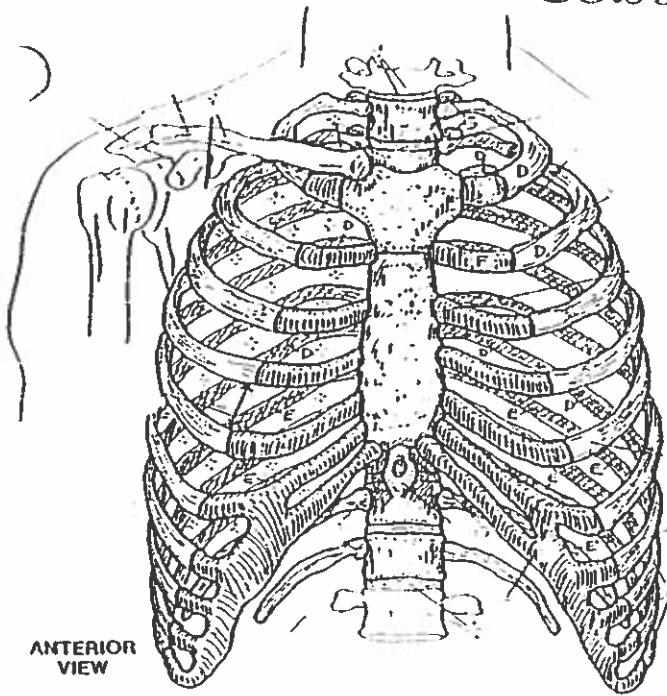


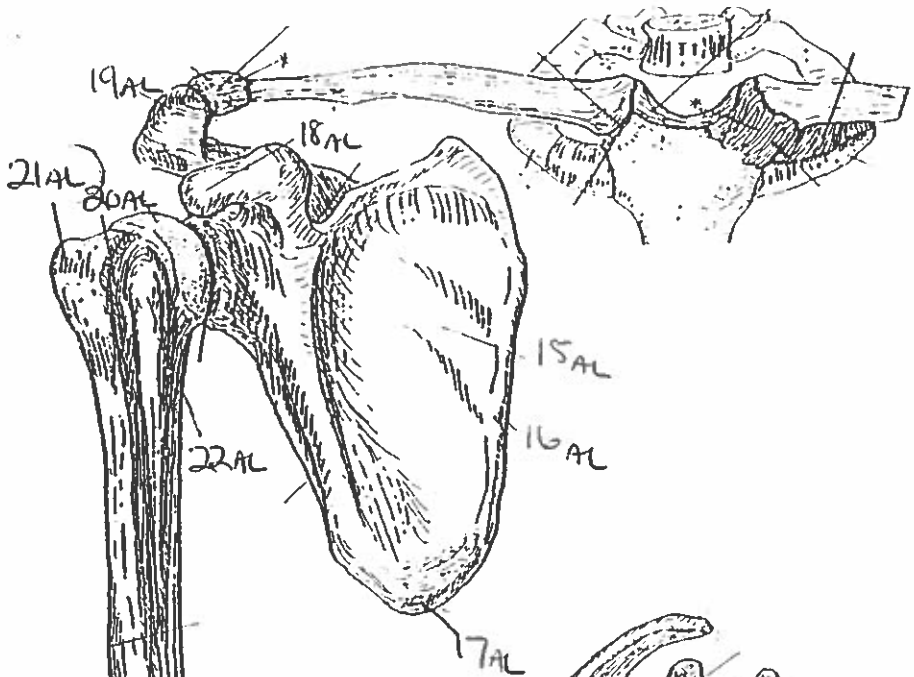
Quiz #7: Upper Body Landmarks.

BONES OF THE SKULL

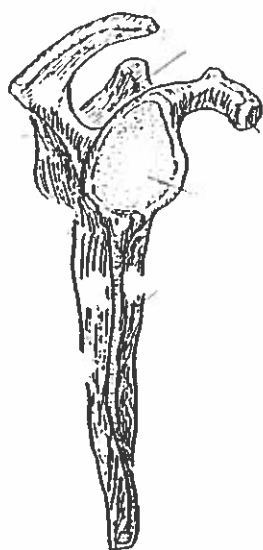


# BONY THORAX

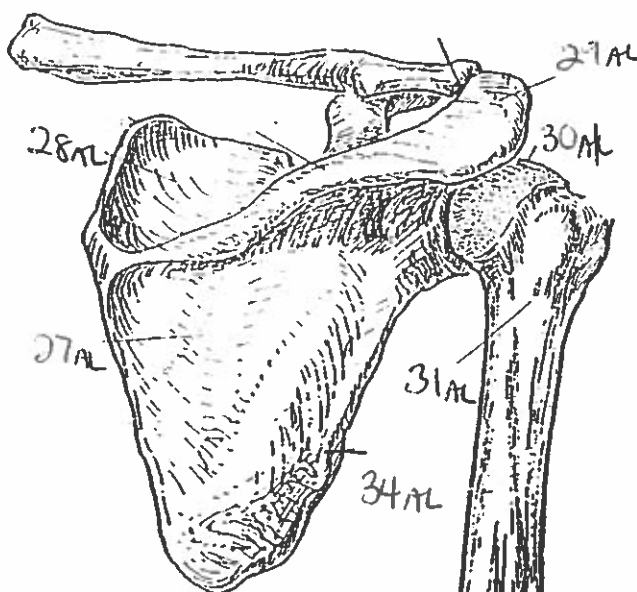




ANTERIOR VIEW  
(Right arm)



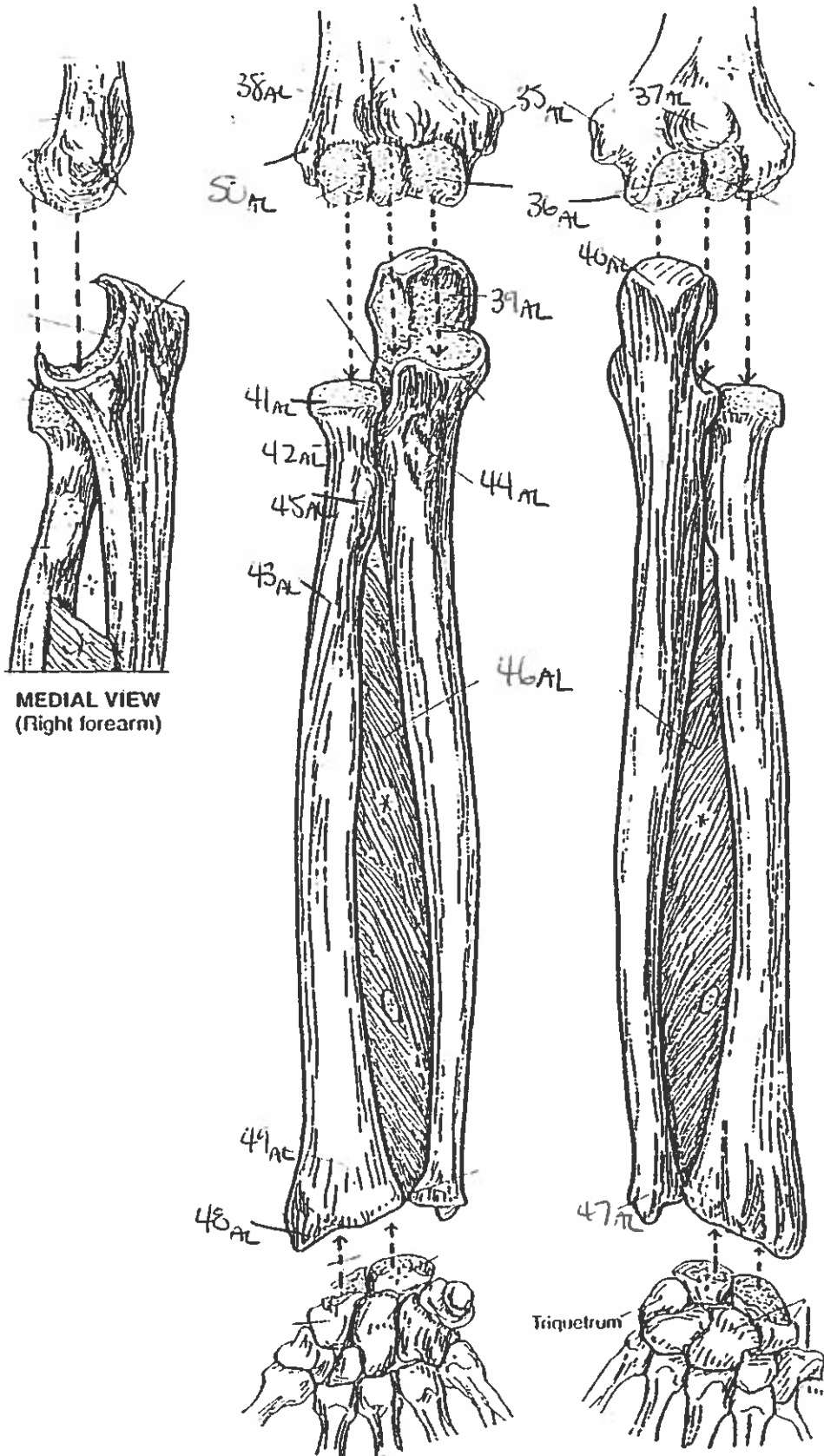
LATERAL VIEW



POSTERIOR VIEW

PECTORAL GIRDLE & ARM BONE  
HUMERUS.

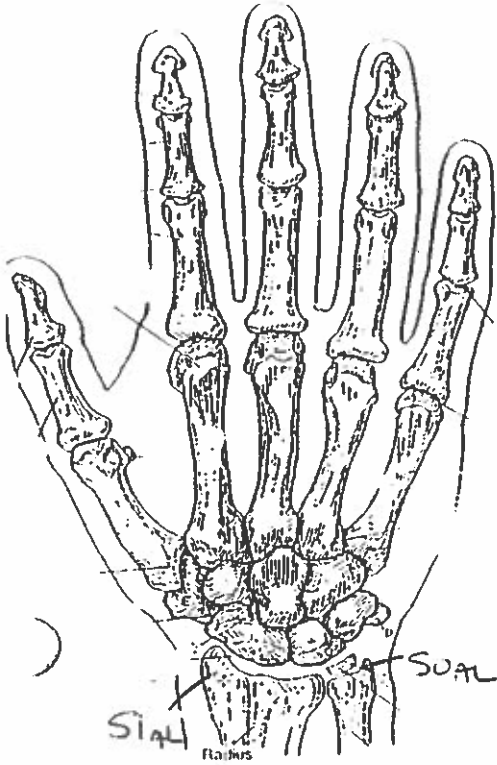
# FOREARM BONES



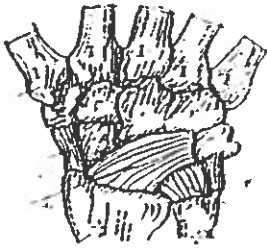
**MEDIAL VIEW**  
(Right forearm)

**ANTERIOR VIEW**  
(Right forearm)

**POSTERIOR VIEW**  
(Right forearm)



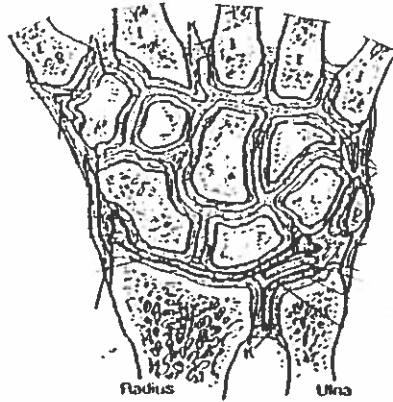
POSTERIOR (DORSAL) VIEW  
(Right hand)



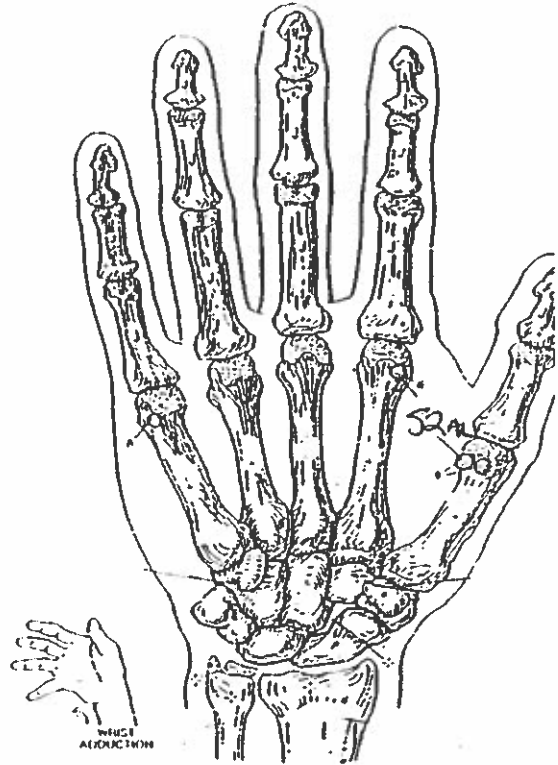
MAJOR LIGAMENTS



CARPAL TUNNEL



JOINTS OF WRIST & CARPALS  
(Dorsal view of frontal section)

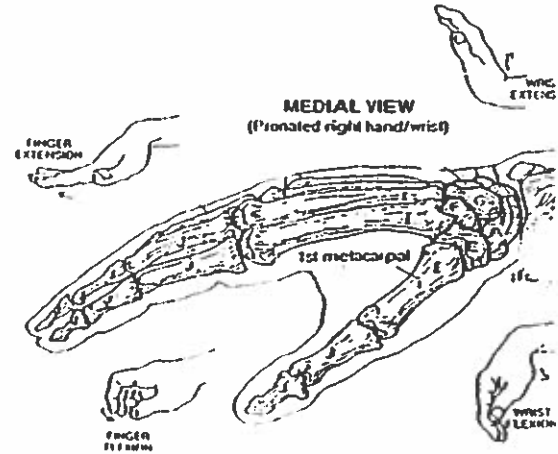


ANTERIOR (PALMAR) VIEW  
(Right hand)



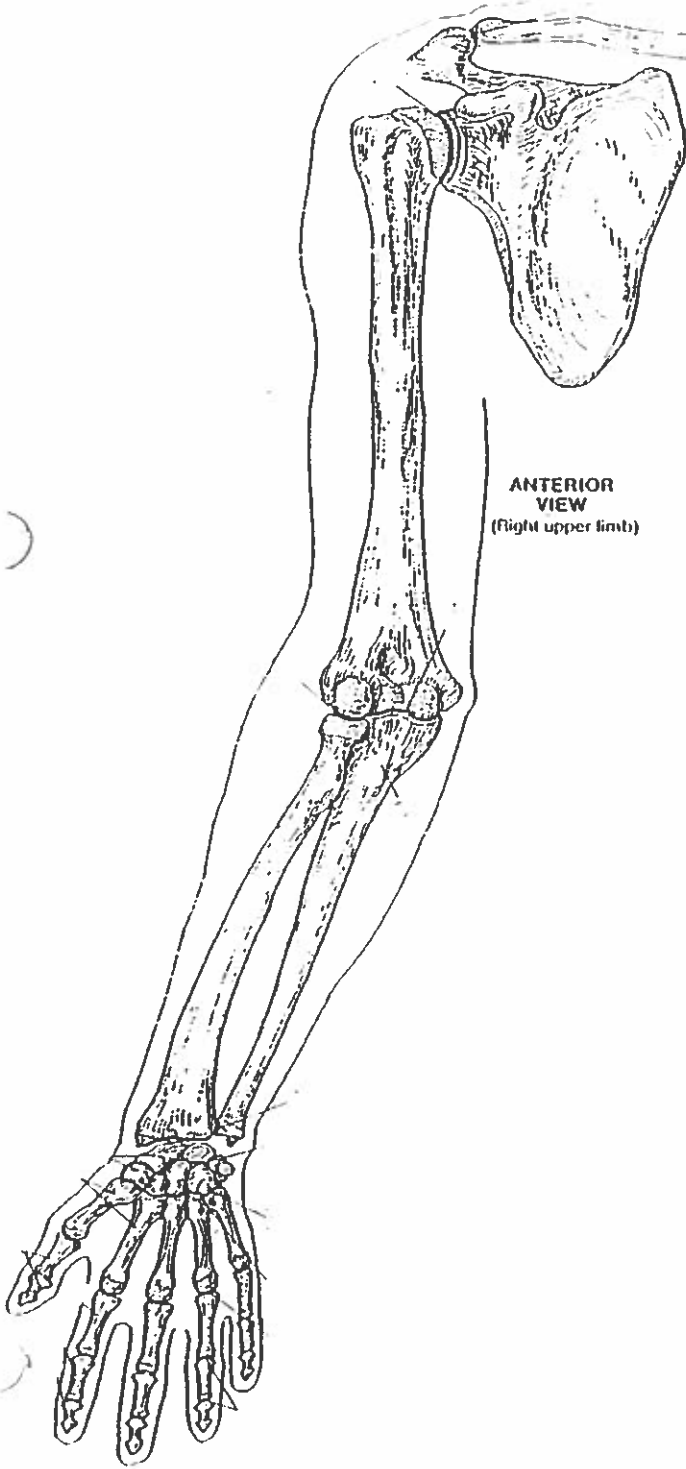
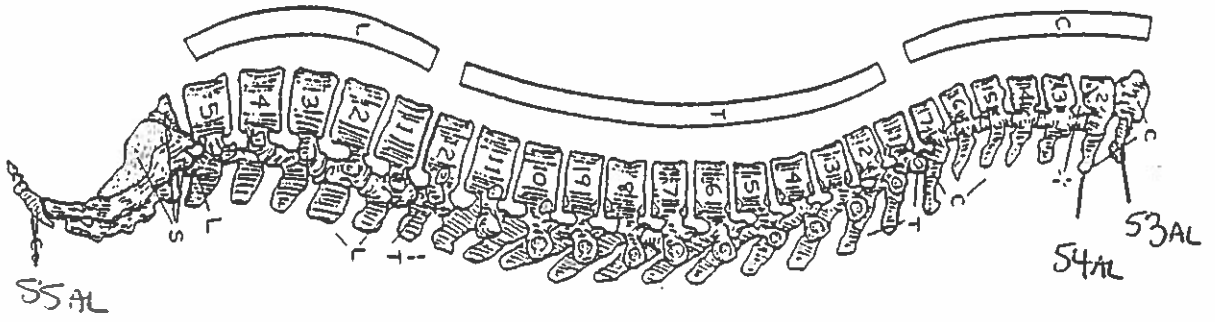
MAJOR LIGAMENTS

## WRIST AND HAND BONES

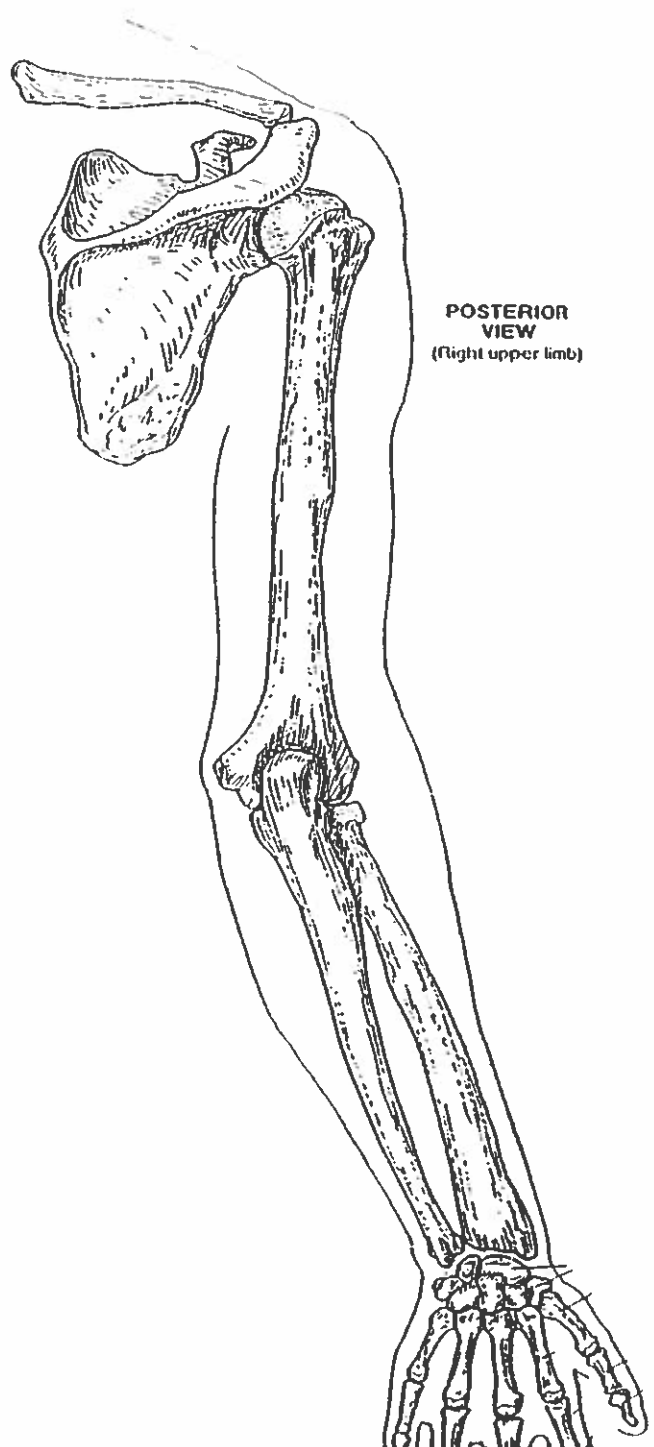


MEDIAL VIEW  
(Pronated right hand/wrist)

# VERTEBRAL COLUMN



**ANTERIOR VIEW**  
(right upper limb)



**POSTERIOR VIEW**  
(right upper limb)

# QUIZ #7. Upper Body Landmarks.

1. supraorbital foramen
2. infraorbital foramen
3. body
4. mental foramen
5. external auditory meatus
6. styloid process
7. zygomatic process
8. anterior nasal spine
9. glabella
10. sagittal suture
11. lambdoidal suture
12. mastoid process
13. coronal suture
14. zygomatic process.
15. subscapular fossa
16. medial margin
17. inferior angle
18. coracoid process
19. acromion
20. intertubercular groove
21. greater tubercle
22. lesser tubercle
23. coronoid fossa
24. medial epicondyle
25. trochlea
26. capitulum
27. infraspinous fossa
28. supraspinous fossa
29. acromion
30. head

31. surgical neck
32. trochlea
33. lateral epicondyle
34. lateral margin
35. medial epicondyle
36. trochlea
37. olecranon fossa
38. coronoid fossa
39. trochlear notch
40. olecranon.
41. ~~trapezium~~ head
42. neck
43. shaft
44. ulna tuberosity
45. radial tuberosity
46. interosseous membrane
47. styloid process of ulna
48. styloid process of radius
49. wrist
50. styloid process of ulna
51. styloid process of radius
52. sesamoid bone.
53. atlas
54. axis
55. coccyx
- ~~56.~~
- ~~57.~~
- ~~58.~~
- ~~59.~~
- 60.