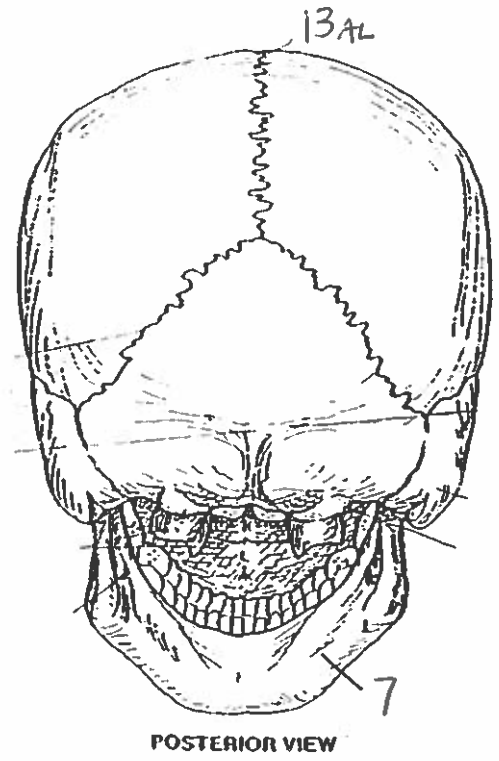
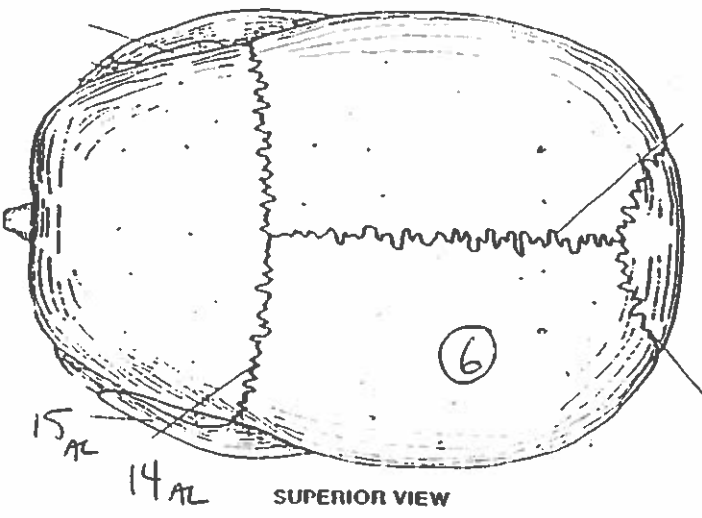
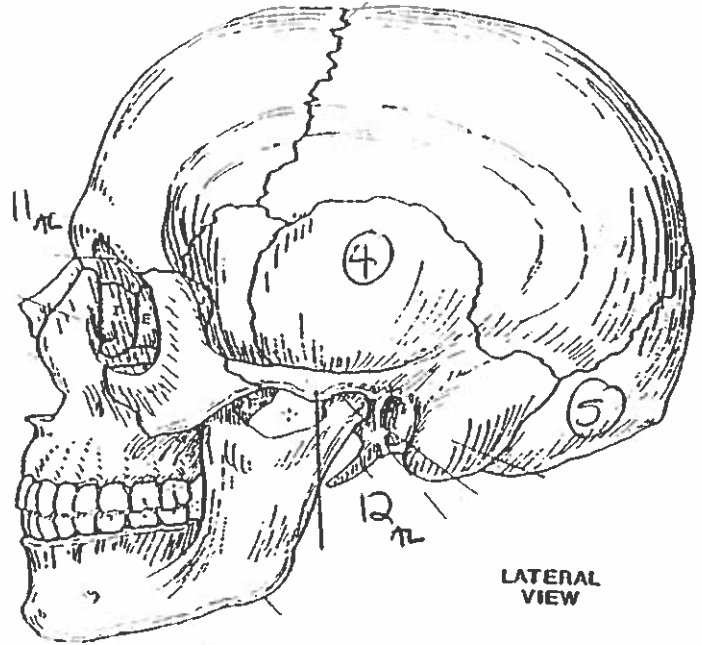
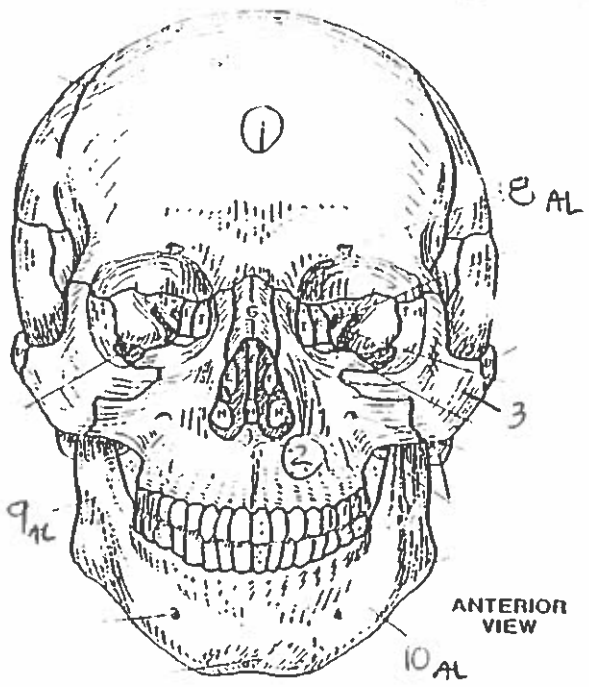
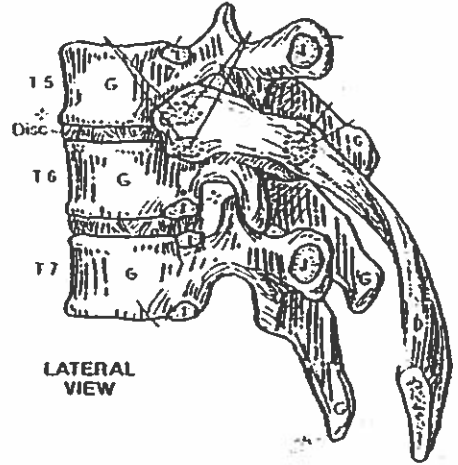
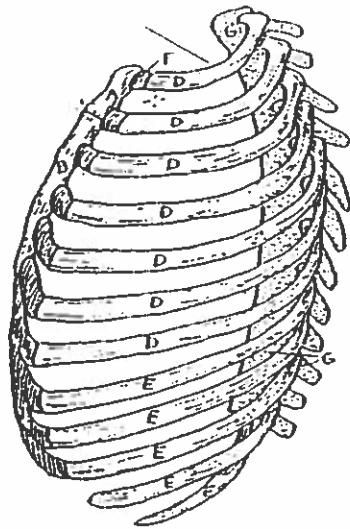

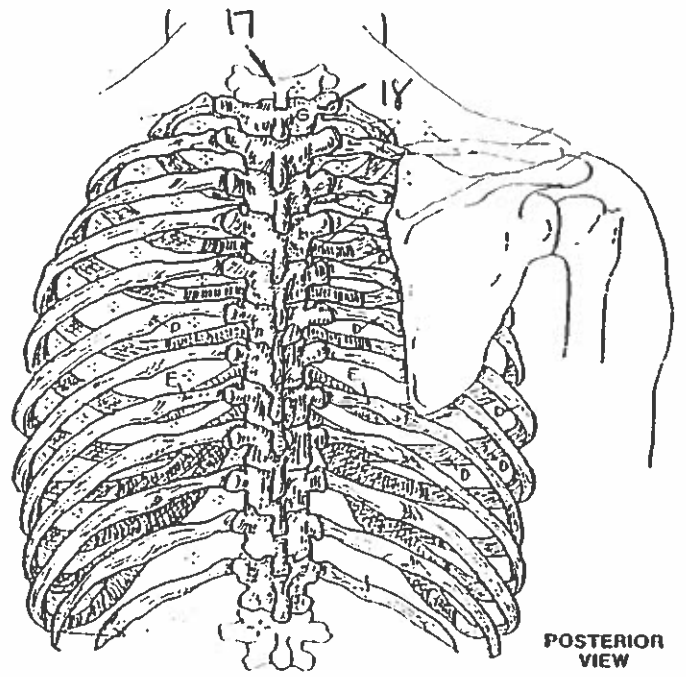
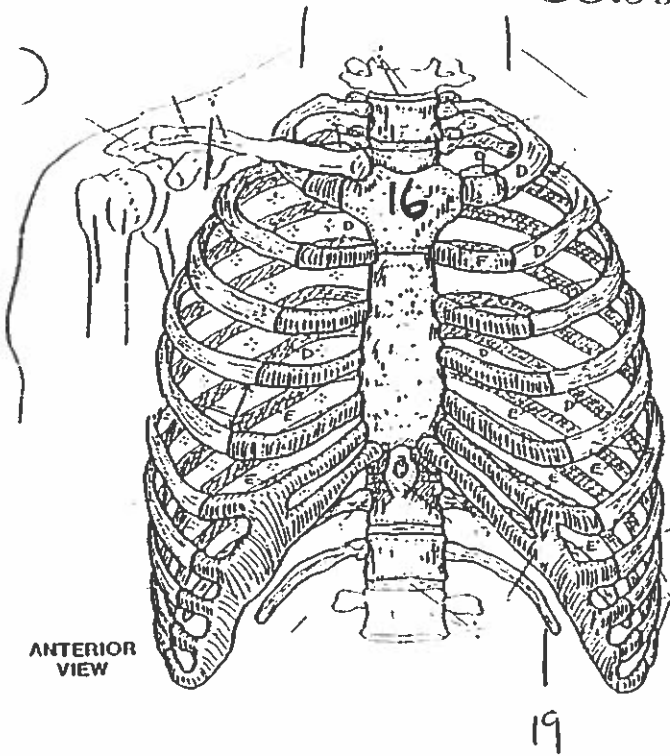
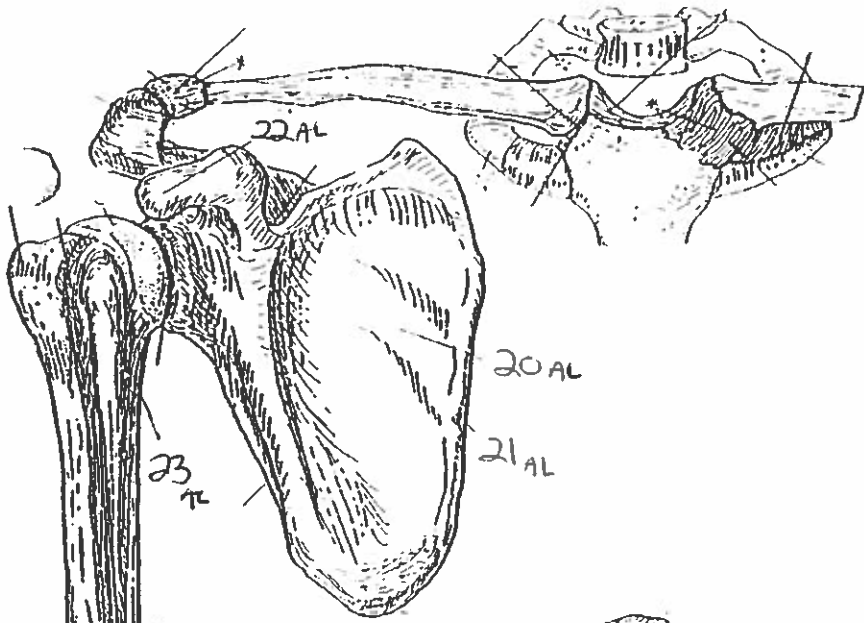


BONES OF THE SKULL.

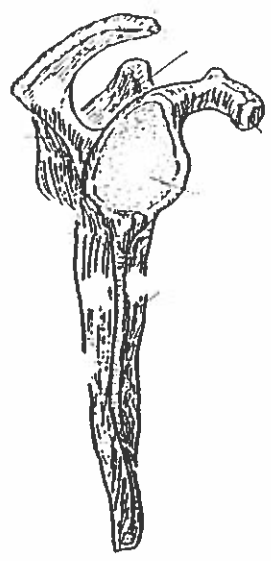


BONY THORAX

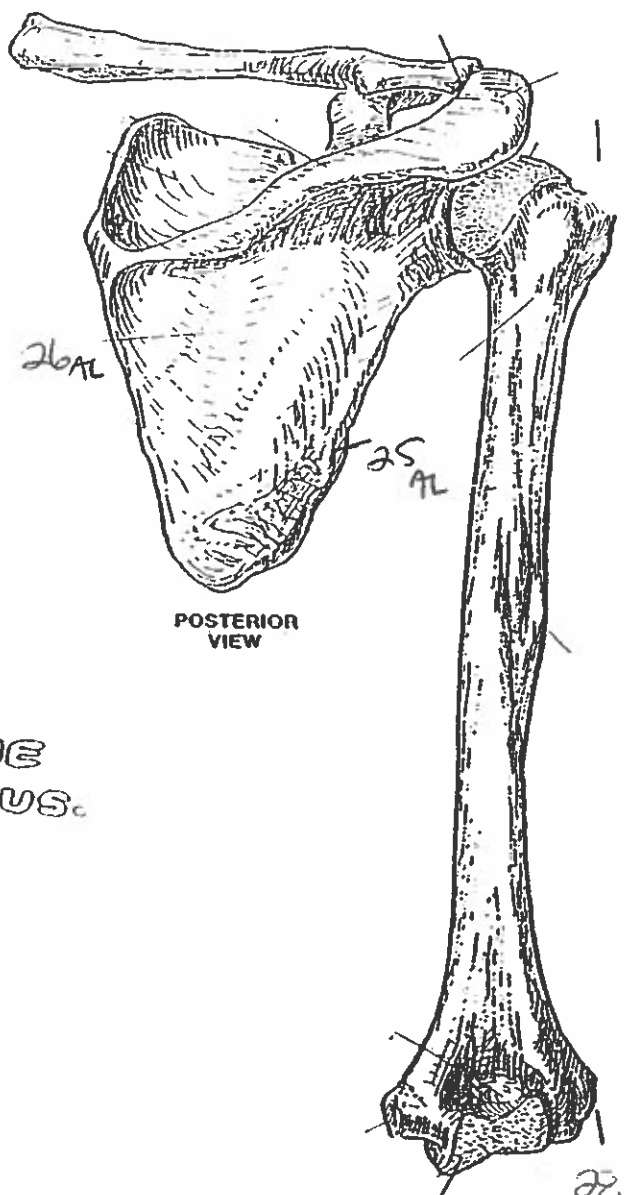




ANTERIOR VIEW
(Right arm)



LATERAL VIEW



POSTERIOR VIEW

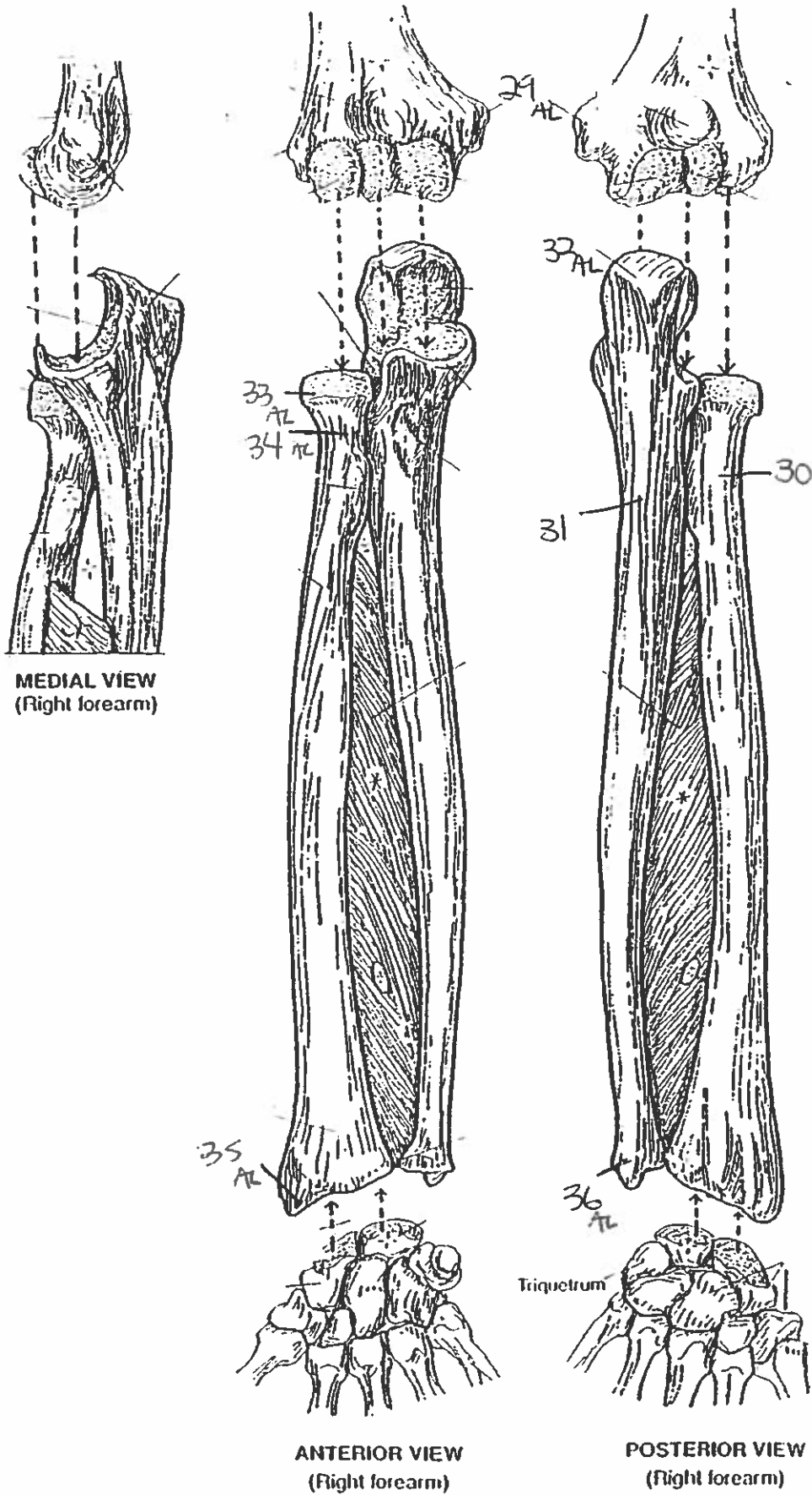
PECTORAL GIRDLE & ARM BONE
HUMERUS.

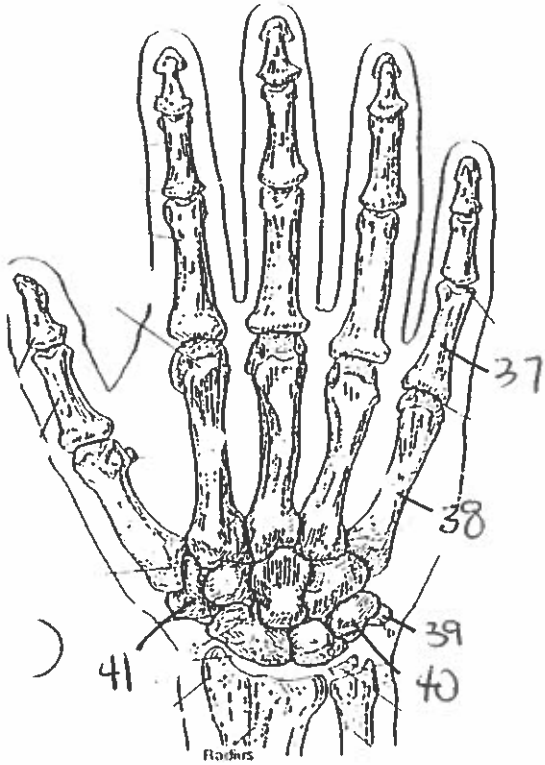
23 AL

24 AL

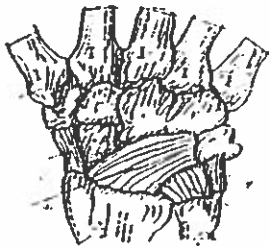
28 AL

FOREARM BONES

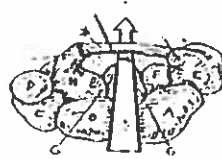




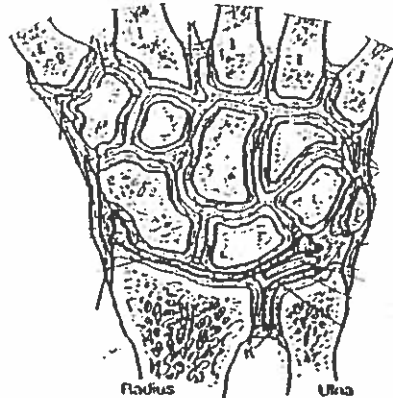
POSTERIOR (DORSAL) VIEW
(Right hand)



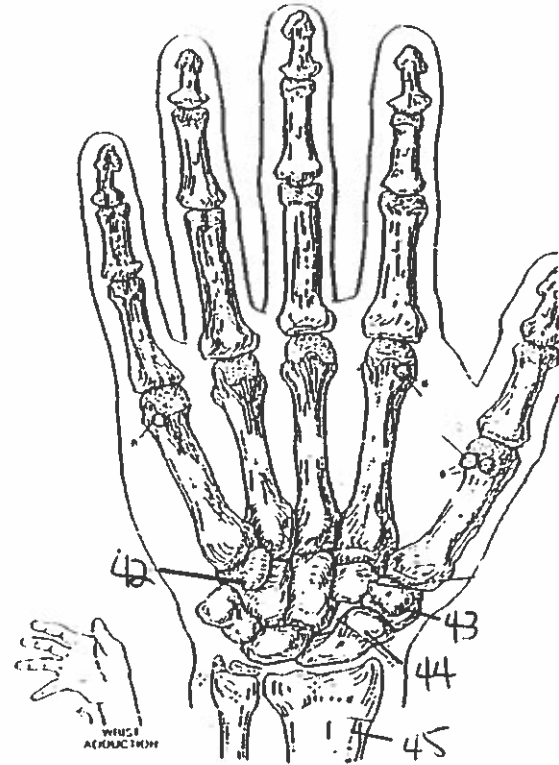
MAJOR LIGAMENTS



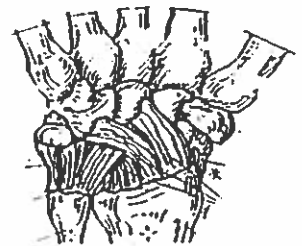CARPAL TUNNEL



JOINTS OF WRIST & CARPALS
(Dorsal view of frontal section)

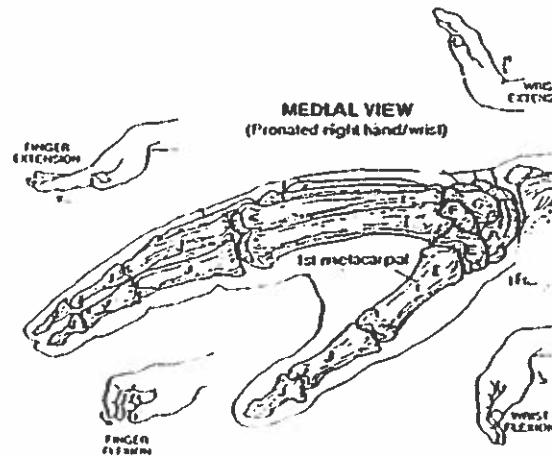


ANTERIOR (PALMAR) VIEW
(Right hand)



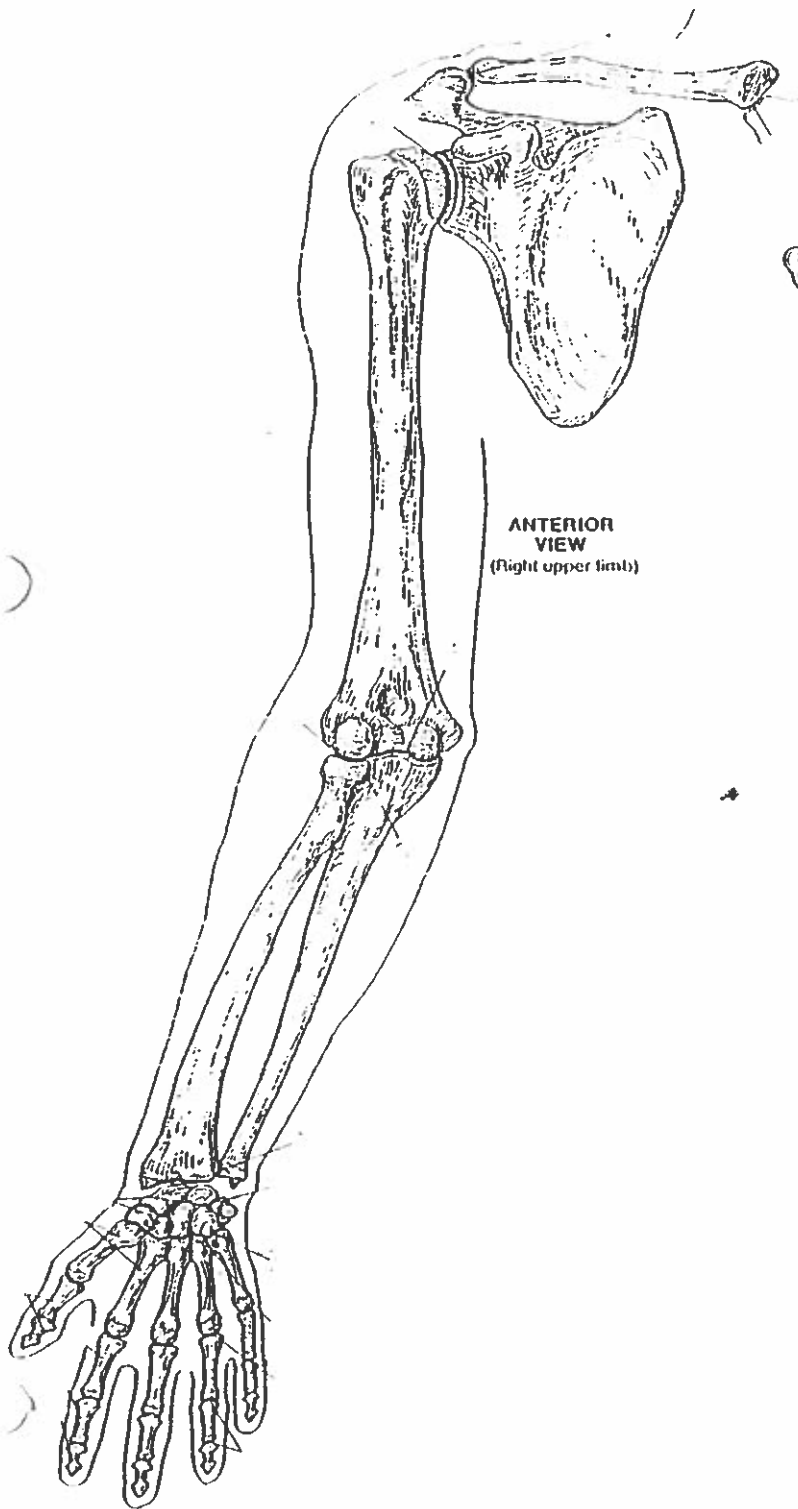
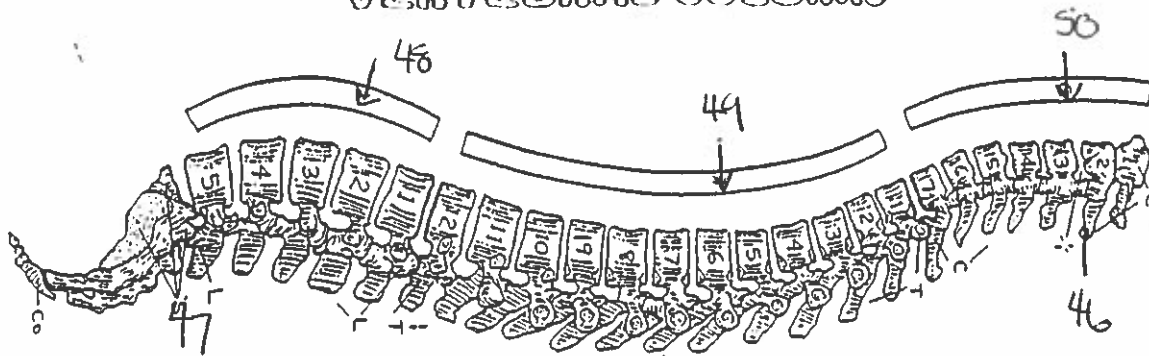
MAJOR LIGAMENTS

WRIST AND HAND BONES

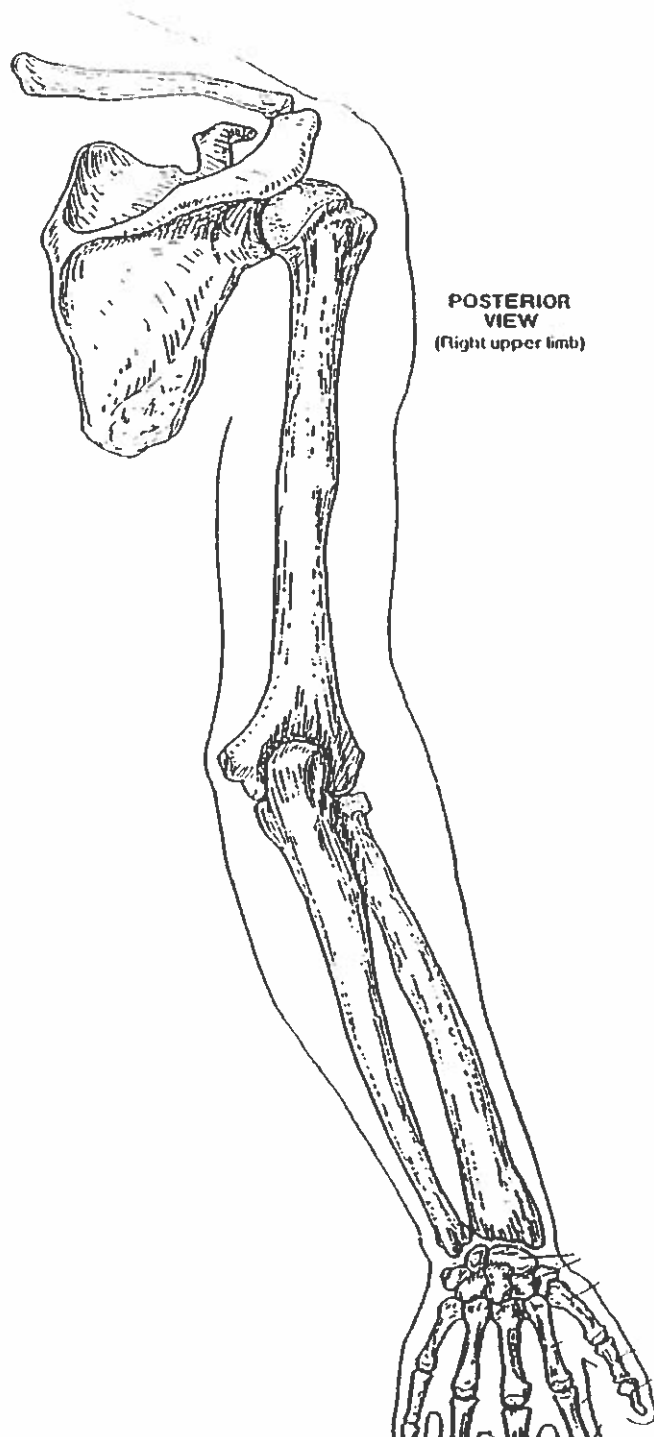


MEDIAL VIEW
(Pronated right hand/wrist)

VERTEBRAL COLUMN



ANTERIOR VIEW
(Right upper limb)



POSTERIOR VIEW
(Right upper limb)

Quiz # 4' upper Body.

1. frontal bone
2. maxilla bone
3. zygomatic bone
4. temporal bone
5. occipital bone
6. parietal bone
7. mandible.
8. supraorbital suture
9. ramus
10. body
11. glabella
12. styloid process
13. sagittal suture
14. coronal suture
15. zygomatic process
16. manubrium
17. atlas
18. axis
19. floating ribs
20. subscapular fossa
21. medial margin
22. coracoid process
23. lesser trochanter
24. medial epicondyle
25. lateral margin
26. infraspinous fossa
27. trochlea
28. lateral epicondyle
29. medial epicondyle
30. radius bone
31. ulna bone
32. olecranon
33. head
34. neck
35. styloid process of the radius
36. styloid process of the ulna
37. phalanges
38. metacarpals
39. pisiform
40. triquetrum
41. trapezium
42. hamate
43. trapezium
44. scaphoid
45. radius
46. axis bone
47. sacrum
48. lumbar vertebra.
49. thoracic vertebra.
50. cervical vertebra.