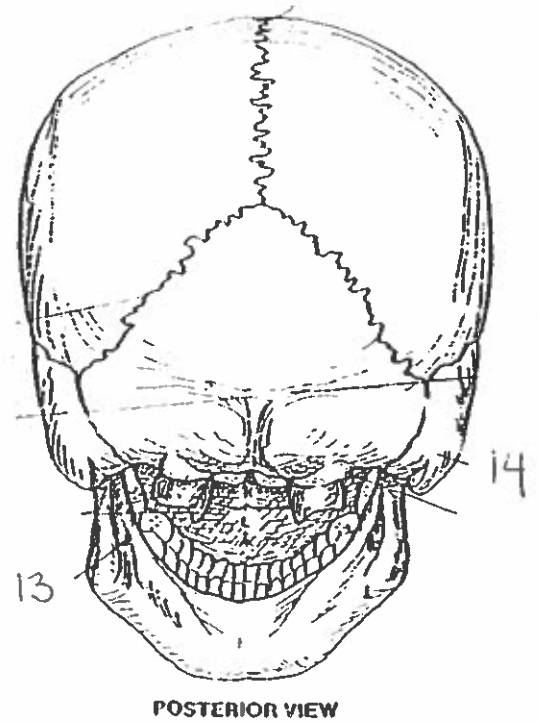
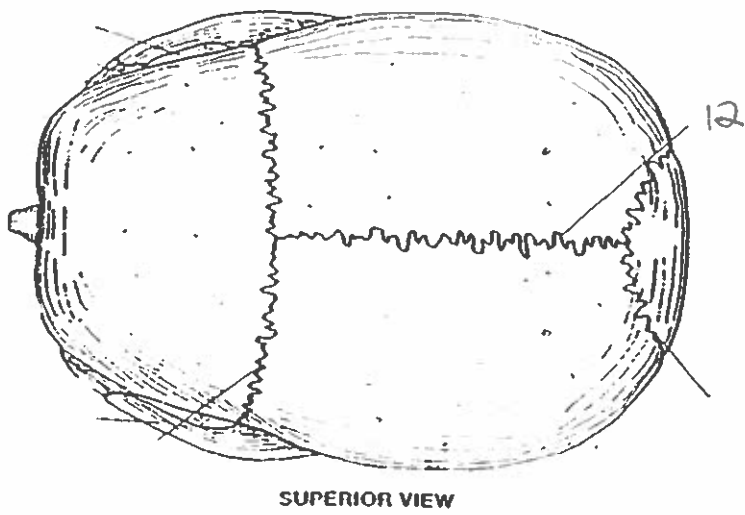
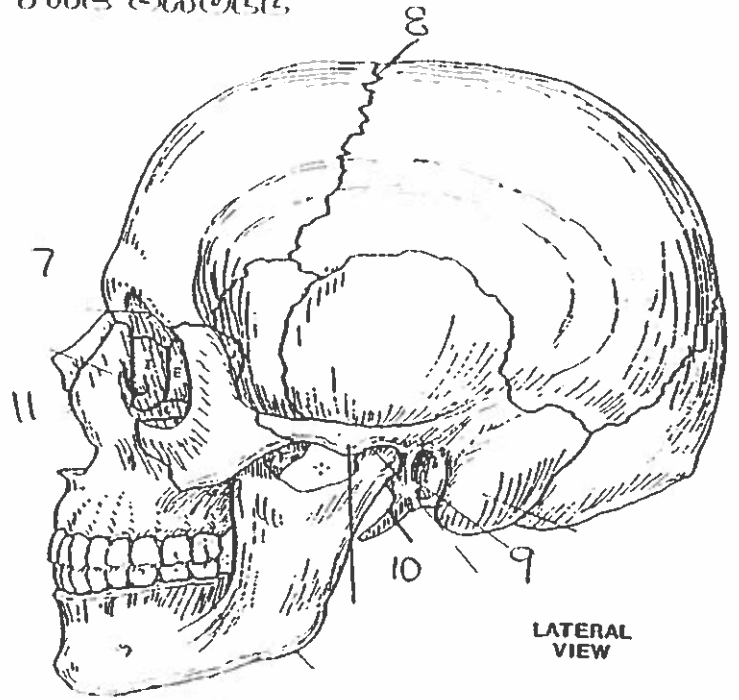
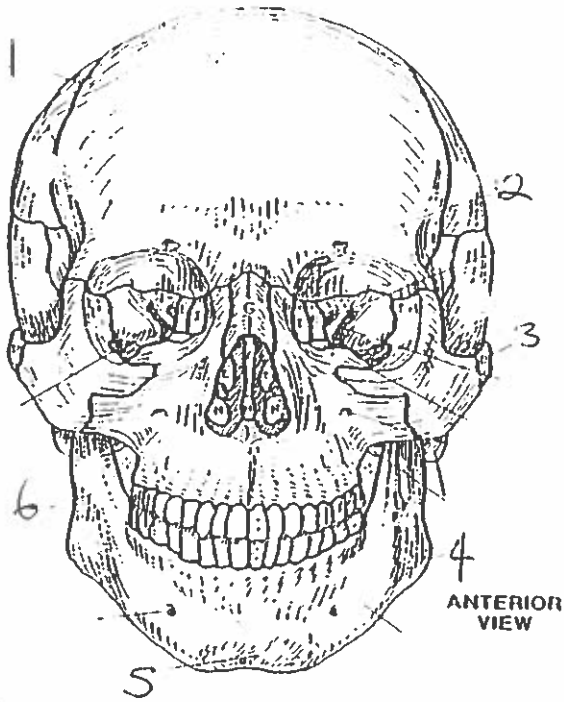
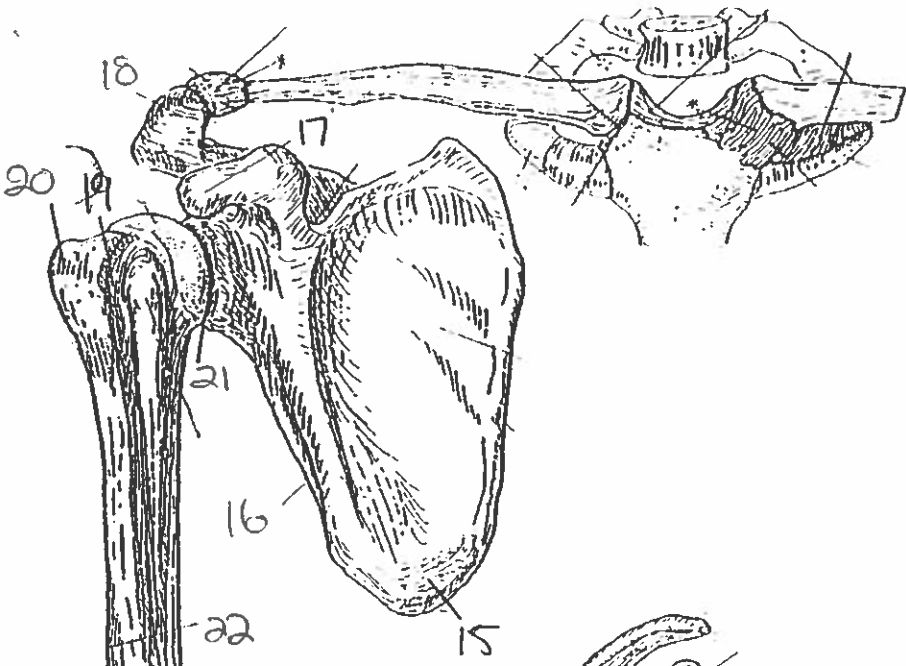


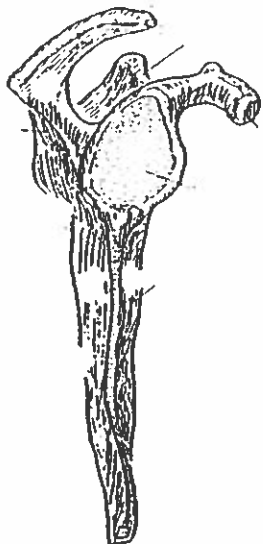
Quiz #9 All Landmarks.

BONES OF THE SKULL.

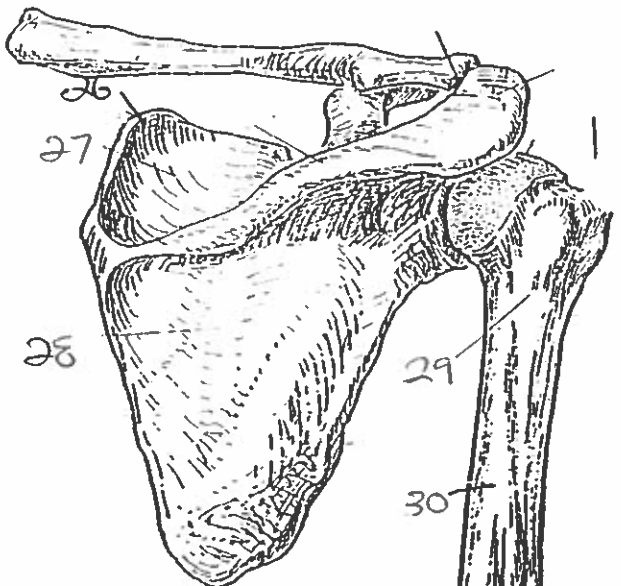




ANTERIOR VIEW
(Right arm)

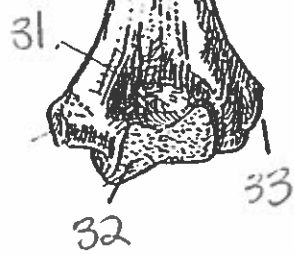


LATERAL VIEW

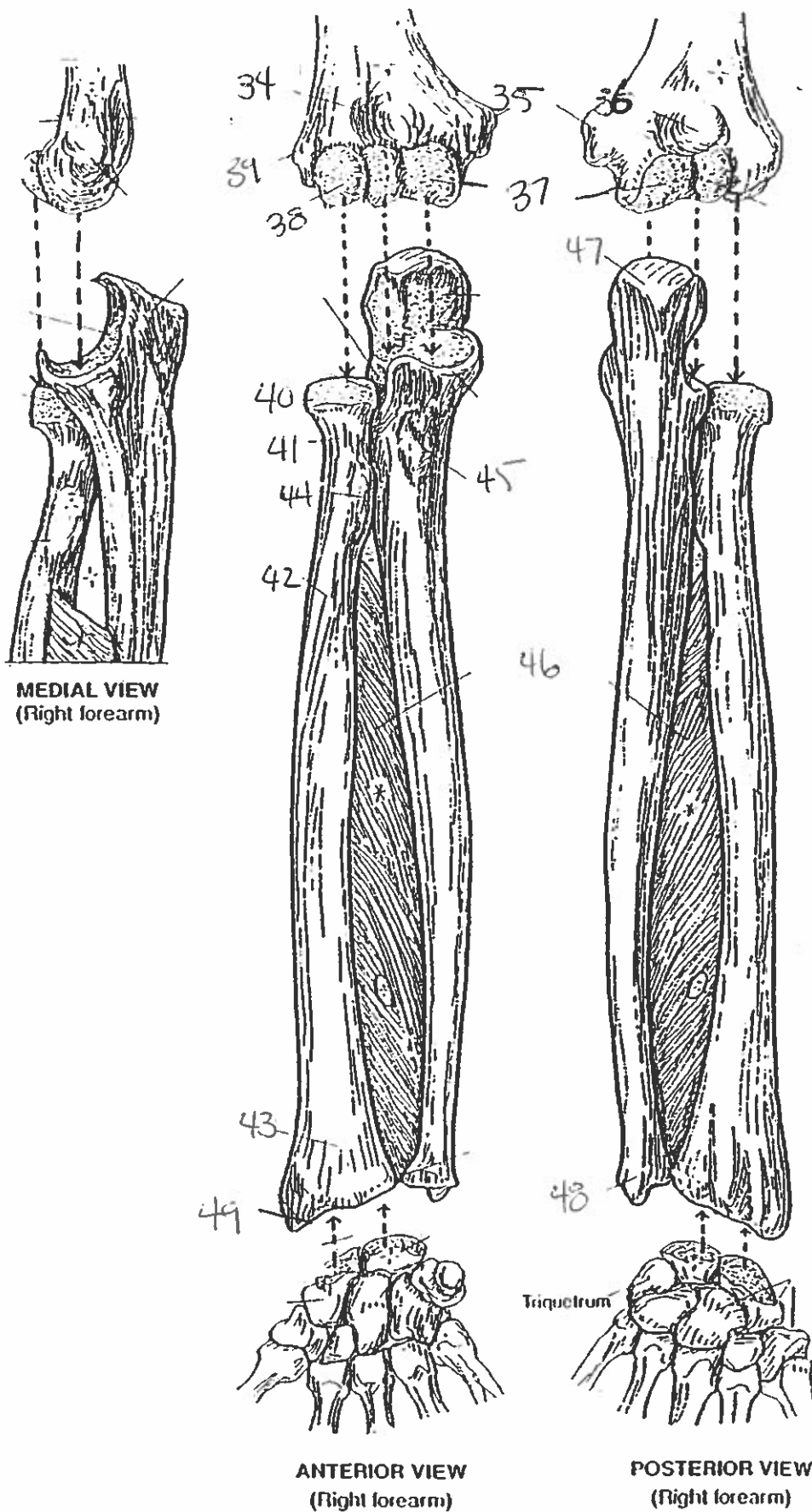


POSTERIOR VIEW

PECTORAL GIRDLE & ARM BONE
HUMERUS.



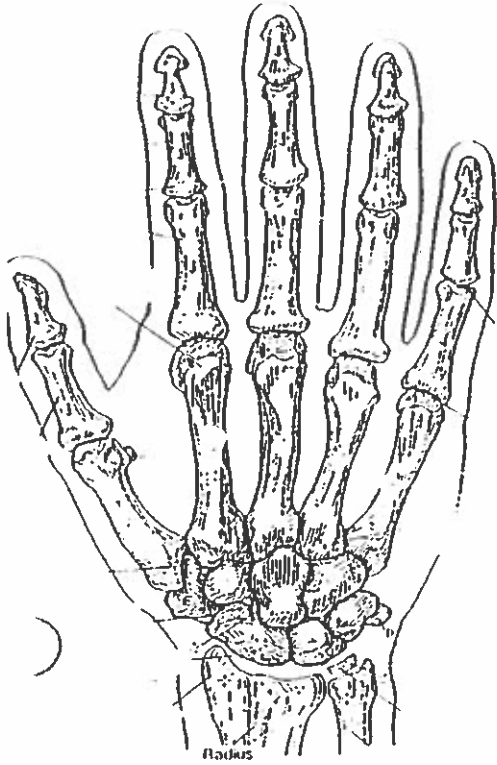FOREARM BONES



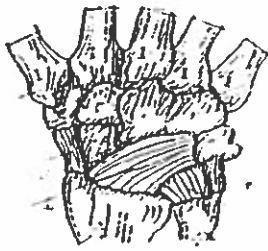
MEDIAL VIEW
(Right forearm)

ANTERIOR VIEW
(Right forearm)

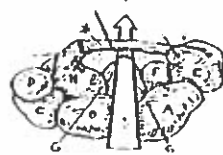
POSTERIOR VIEW
(Right forearm)



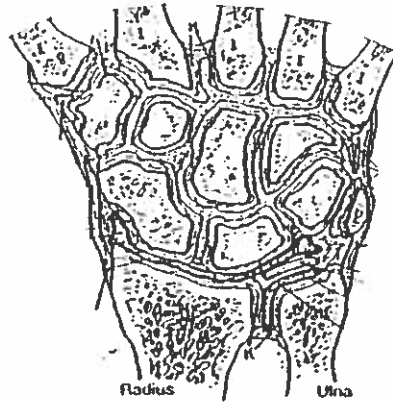
POSTERIOR (DORSAL) VIEW
(Right hand)



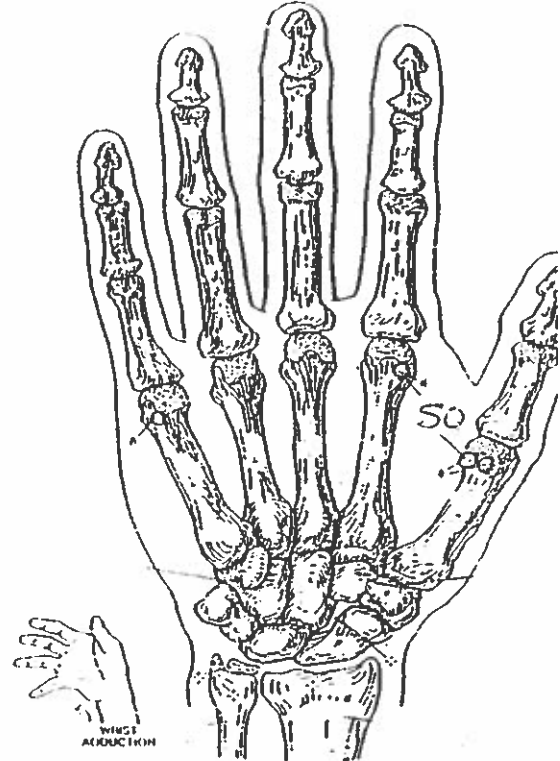
MAJOR LIGAMENTS



CARPAL TUNNEL



JOINTS OF WRIST & CARPALS
(Dorsal view of frontal section)

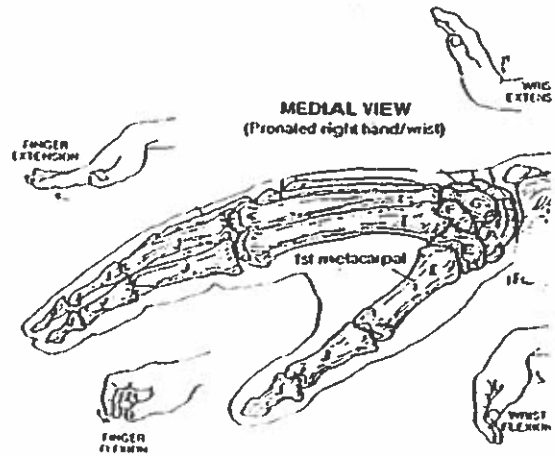


ANTERIOR (PALMAR) VIEW
(Right hand)



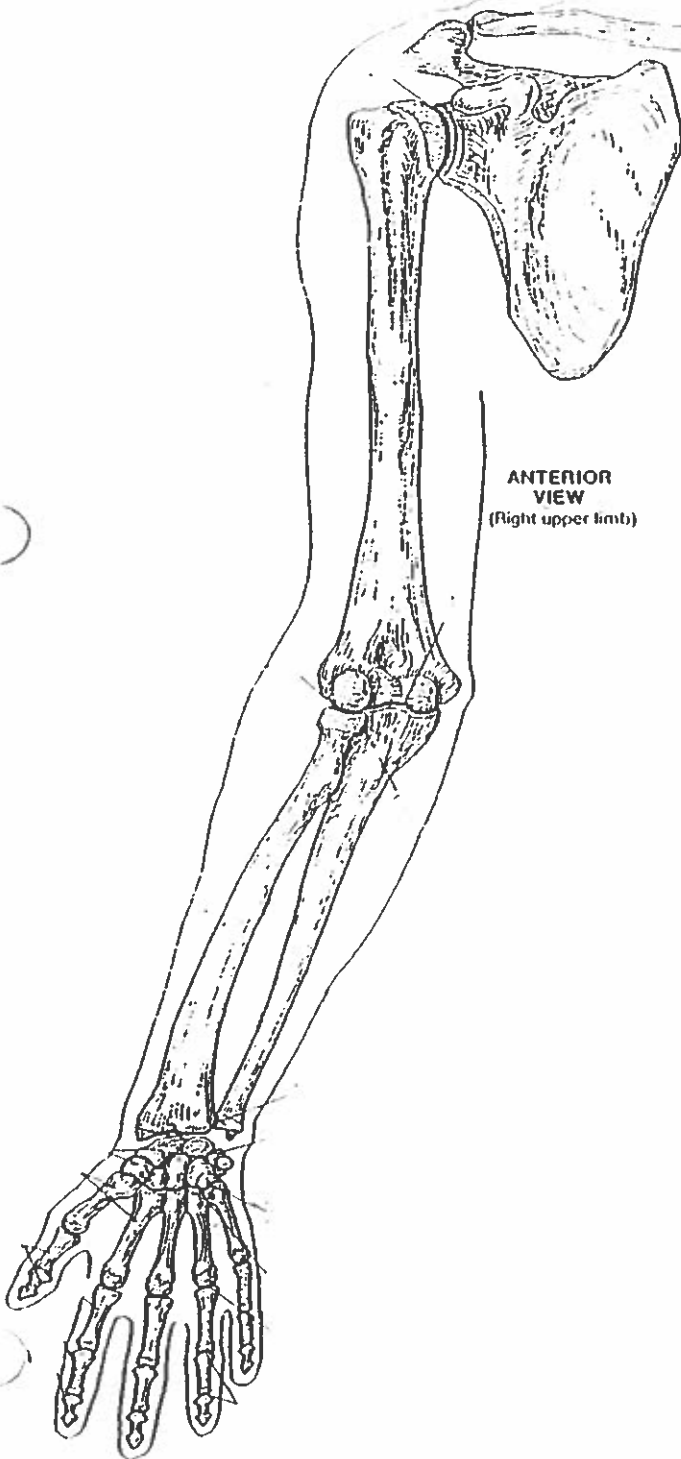
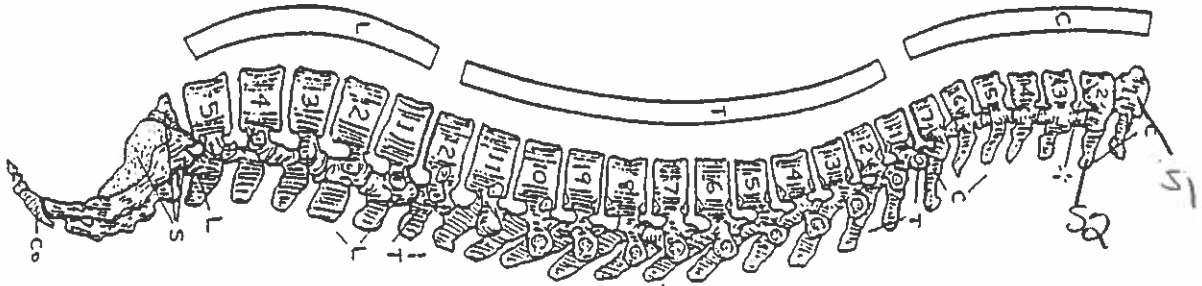
MAJOR LIGAMENTS

WRIST AND HAND BONES

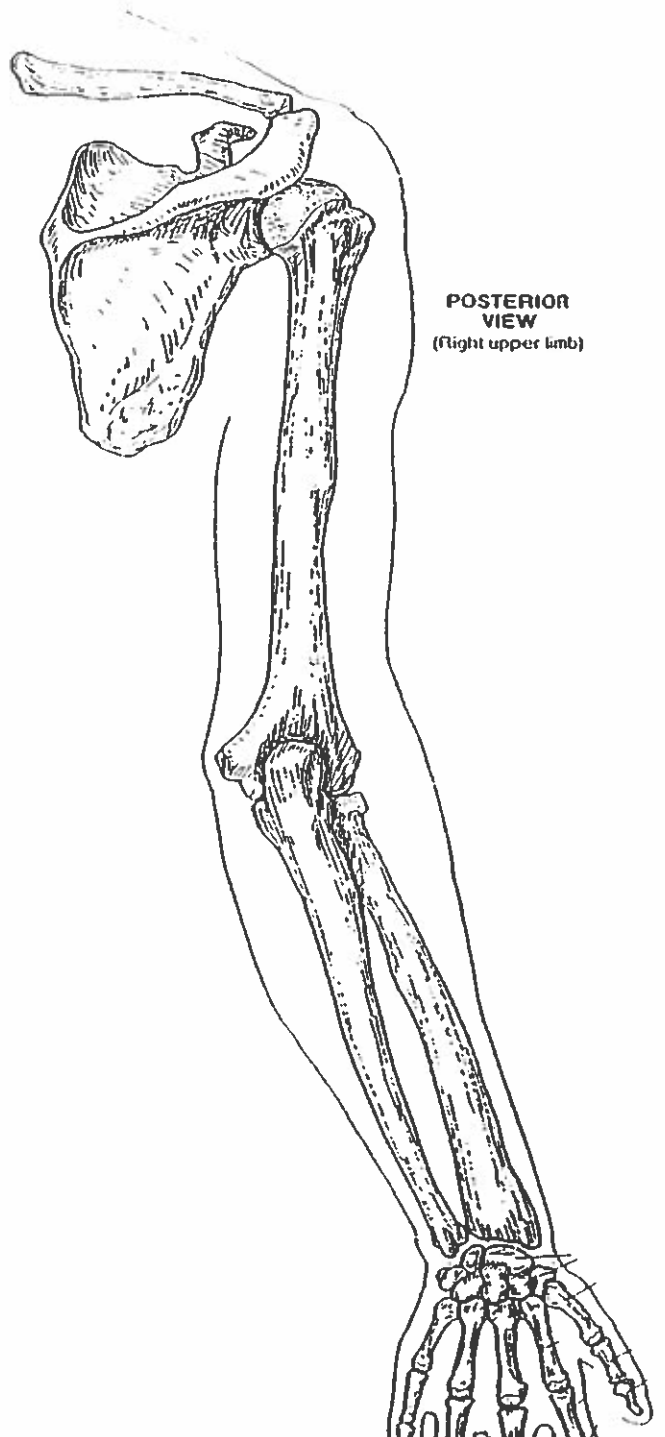


MEDIAL VIEW
(Pronated right hand/wrist)

VERTEBRAL COLUMN



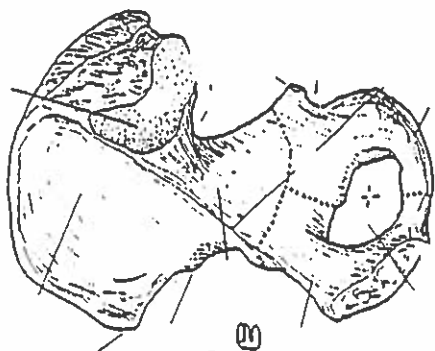
ANTERIOR VIEW
(right upper limb)



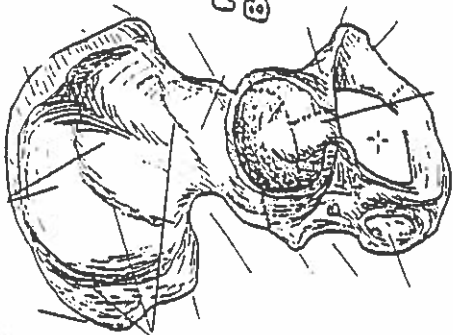
POSTERIOR VIEW
(right upper limb)

HIP BONE, PELVIC GIRDLE, & PELVIS

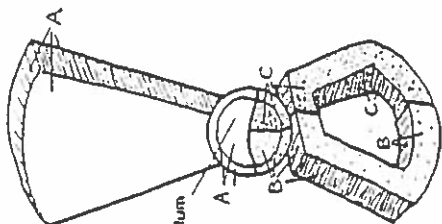
MEDIAL VIEW
(Right bone)



LATERAL VIEW
(Right bone)



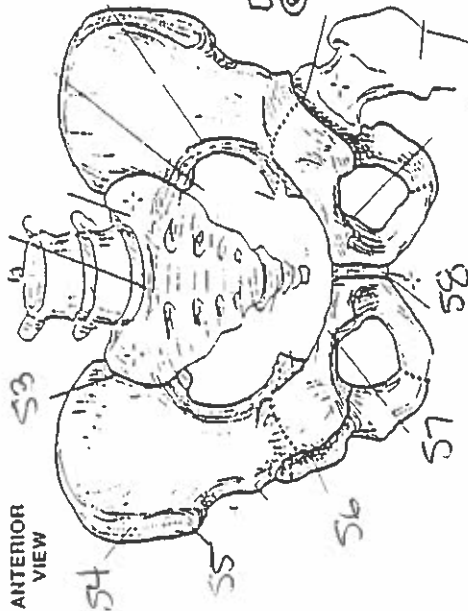
HIP BONE



LATERAL VIEW
(Diagrammatic)

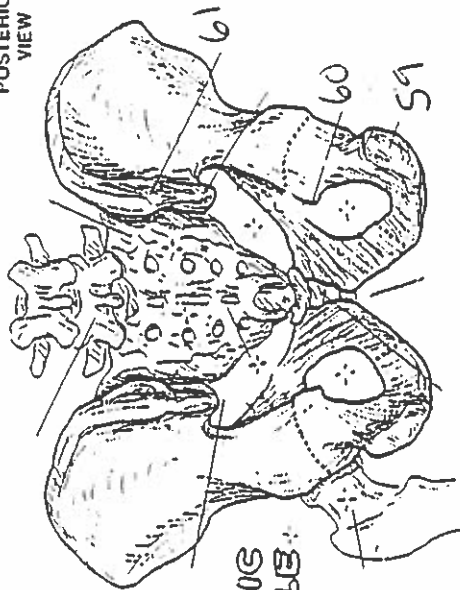
Acetabulum

ANTERIOR VIEW

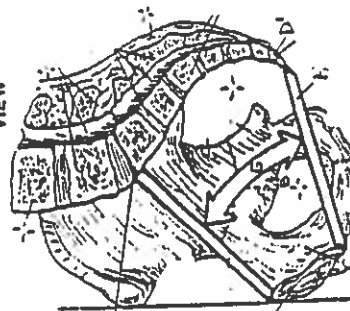


PELVIC GIRDLE

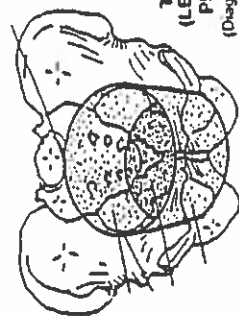
POSTERIOR VIEW



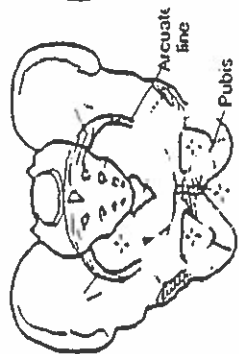
MEDIAL/SAGITTAL VIEW



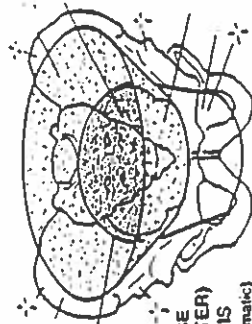
TRUE (LESSER) PELVIS
(Diagrammatic)



PELVIS

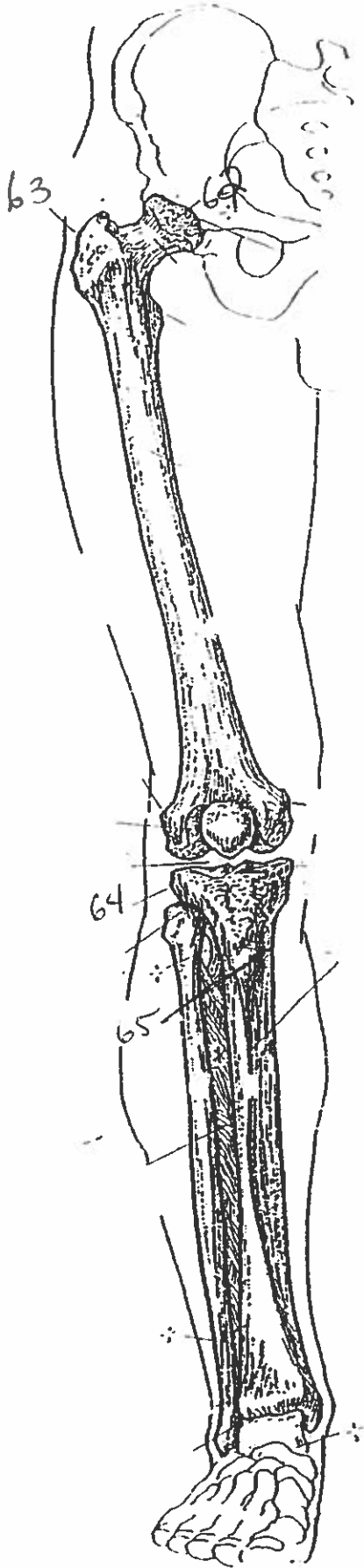


Arcuate line
Pubis

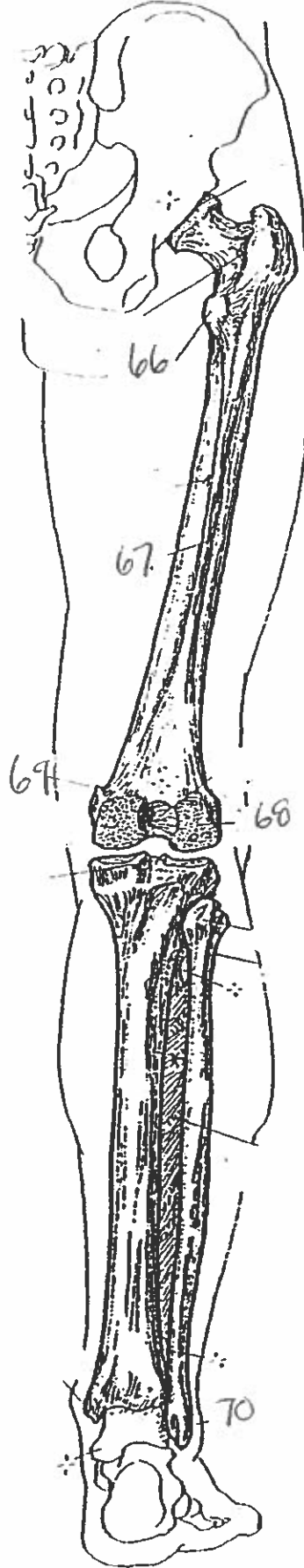


FALSE (GREATER) PELVIS
(Diagrammatic)

ANTERIOR VIEW
(Right limb)



POSTERIOR VIEW
(Right limb)



THIGH & LEG BONES

All Landmarks.

suture

orbital foramen

nasal arch

gle

orbital protuberance

amus

glabella

- 8 coronal suture
9. external auditory meatus
10. styloid process
11. nasal cavity
12. sagittal suture
13. ~~mandibular process~~ mandibular foramen
14. mastoid process
15. inferior angle
16. lateral margin
17. coracoid process
18. acromion
19. intertubercular groove
20. greater trochanter
21. glenohumeral joint
22. deltoid tuberosity
23. coronoid fossa
24. lateral epicondyle
25. trochlea
26. superior angle
27. supraspinous fossa
28. infraspinous fossa
29. surgical neck
30. shaft
31. olecranon fossa
32. trochlea
33. lateral epicondyle.
34. coronoid fossa
35. medial epicondyle

36. olecranon fossa

37. trochlea

38. capitulum

39. lateral epicondyle

40. head

41. neck

42. shaft

43. wrist

44. radial tuberosity

45. ulna tuberosity

46. interosseous membrane

47. olecranon

48. styloid process of ulna

49. styloid process of radius

50. sesamoid bone

51. atlas

52. axis

53. sacroiliac joint

54. iliac crest

55. anterior superior iliac spine.

56. acetabulum

57. superior pubic ramus

58. symphysis pubis

59. posterior superior iliac spine

60. ischial spine

61. ischial tuberosity

62. head

63. greater trochanter

64. lateral epicondyle

65. tibial tuberosity.

66. lesser trochanter

67. linea aspera

68. lateral condyle

69. adductor tubercle

70. lateral malleolus