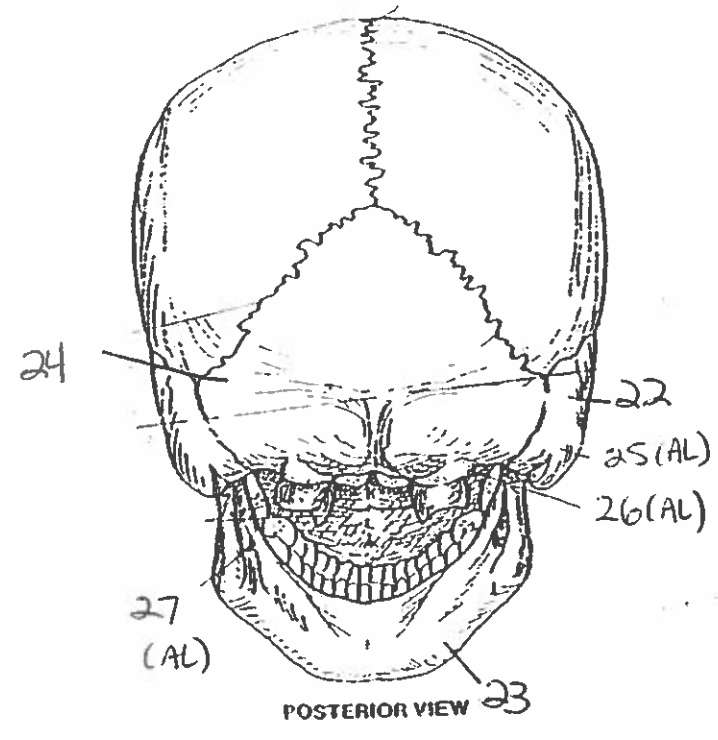
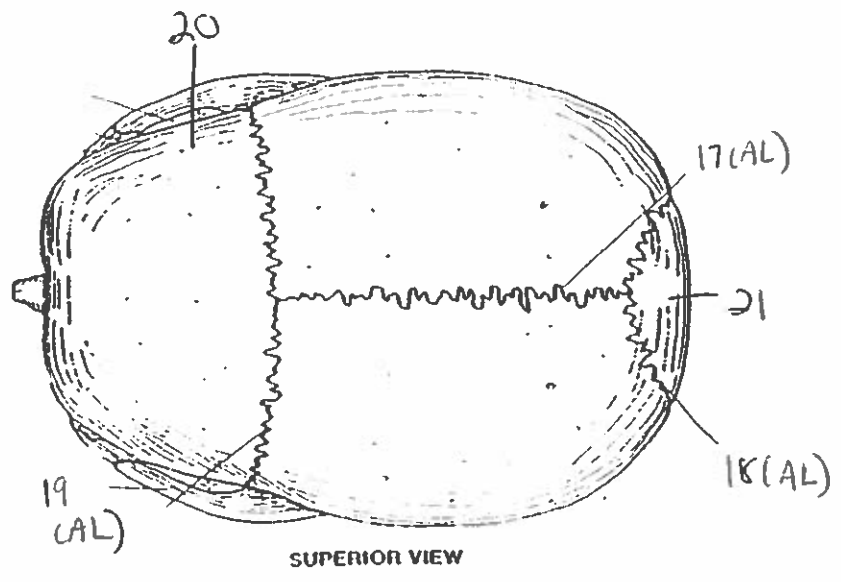
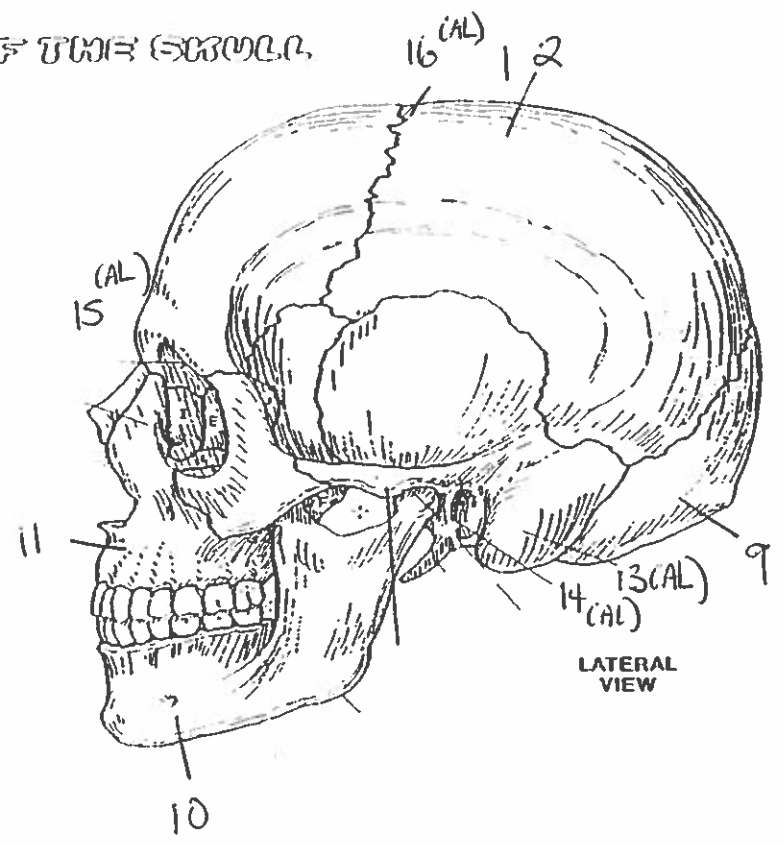
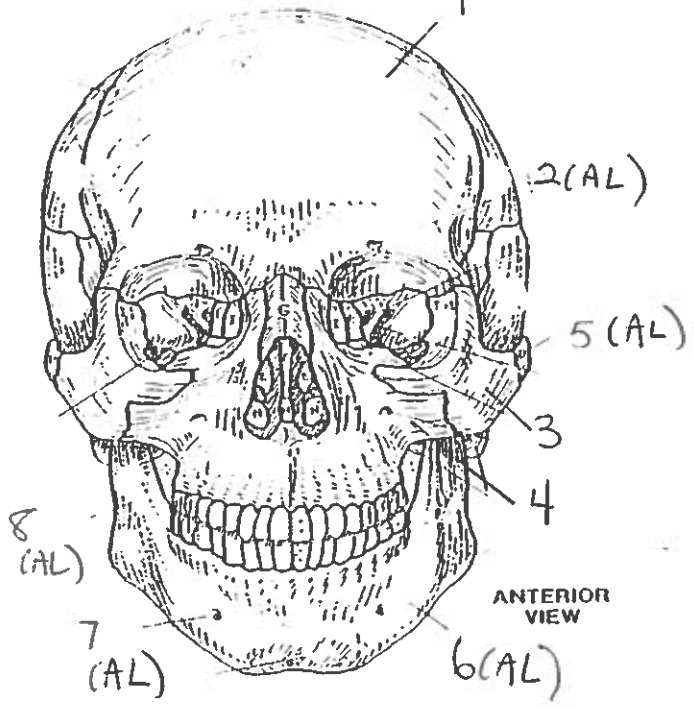
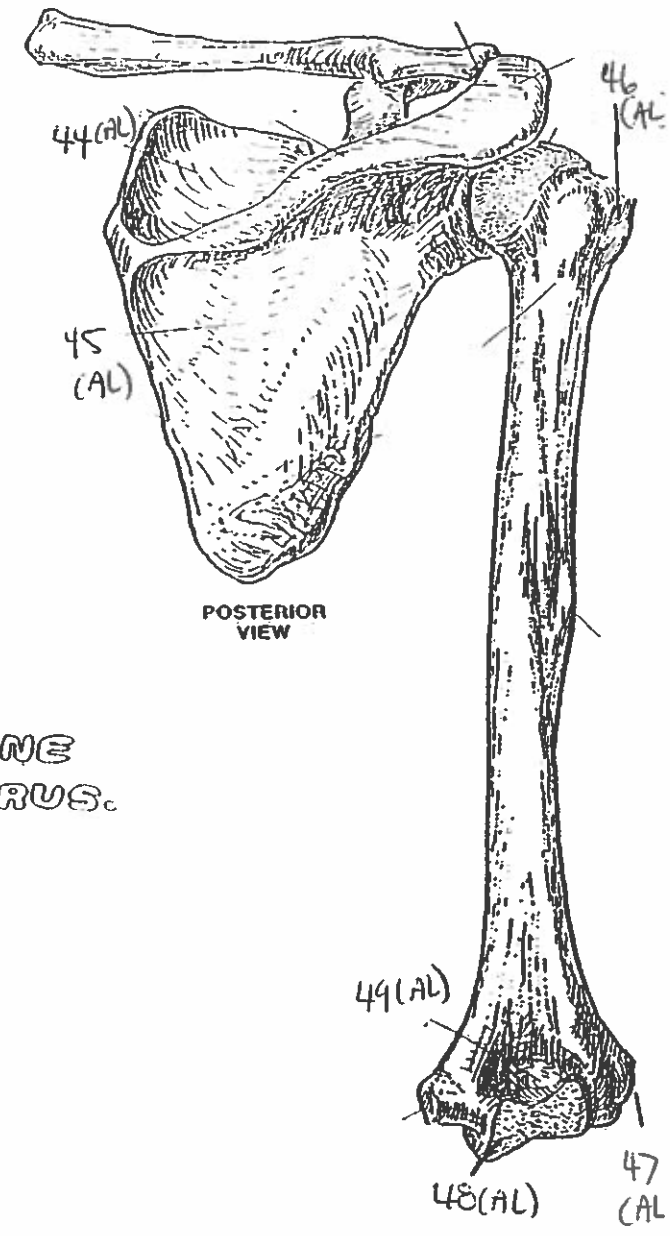
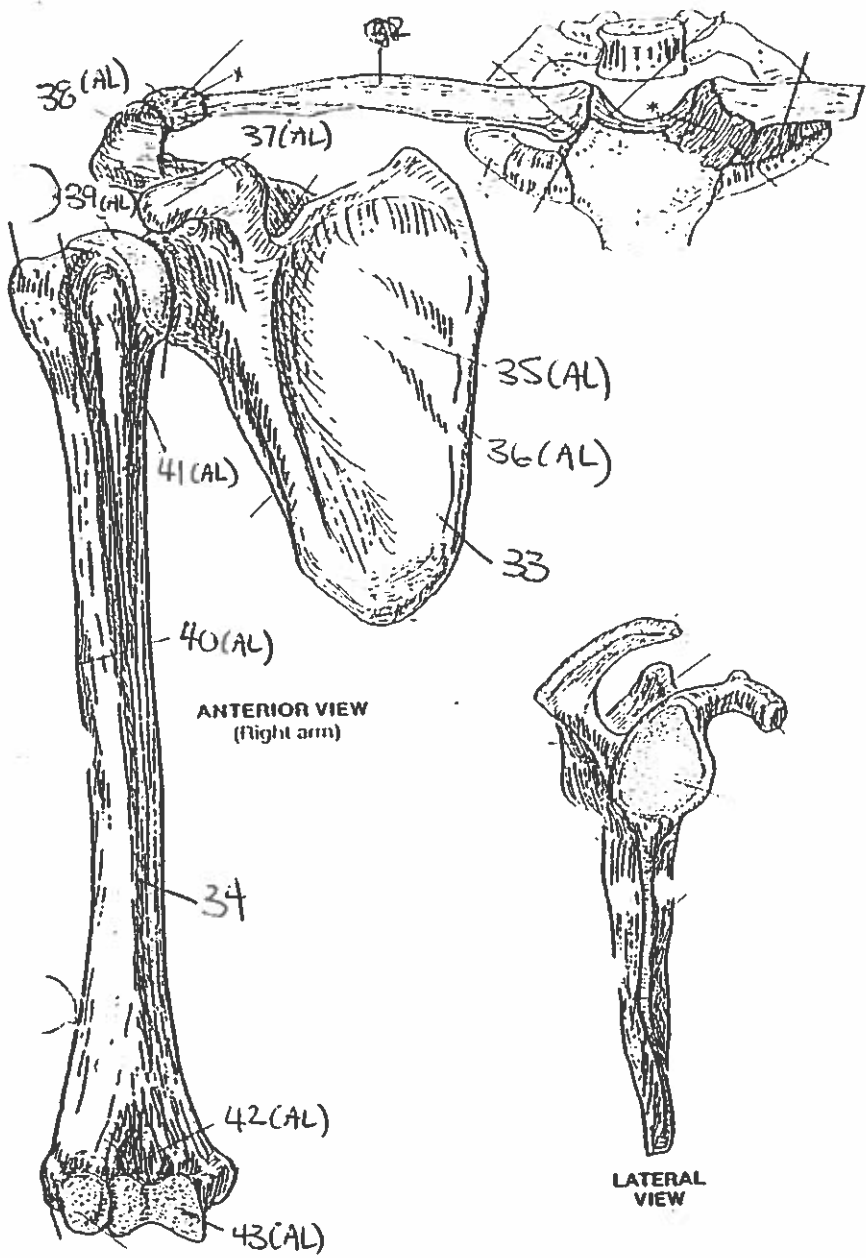


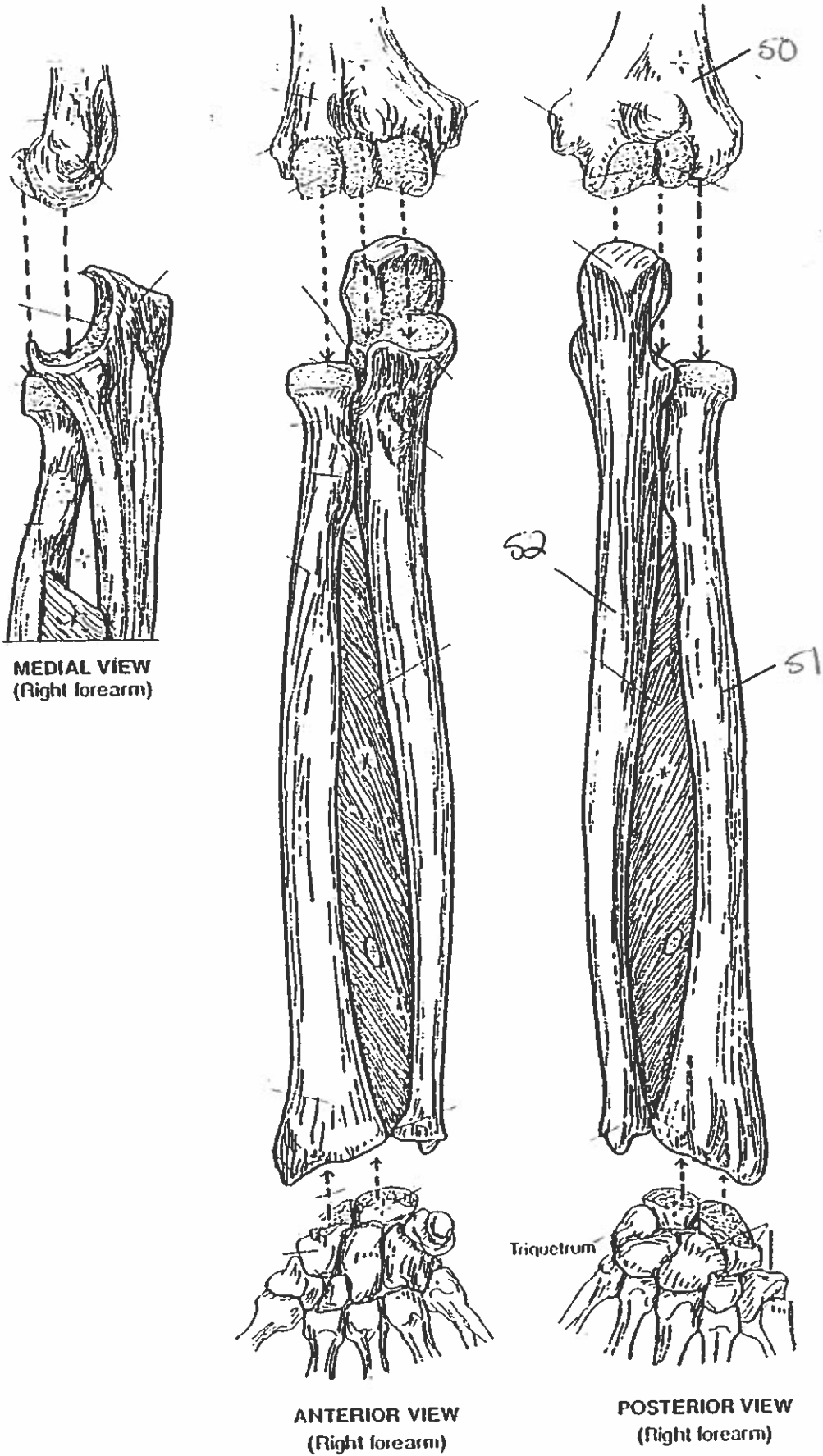
BONES OF THE SKULL

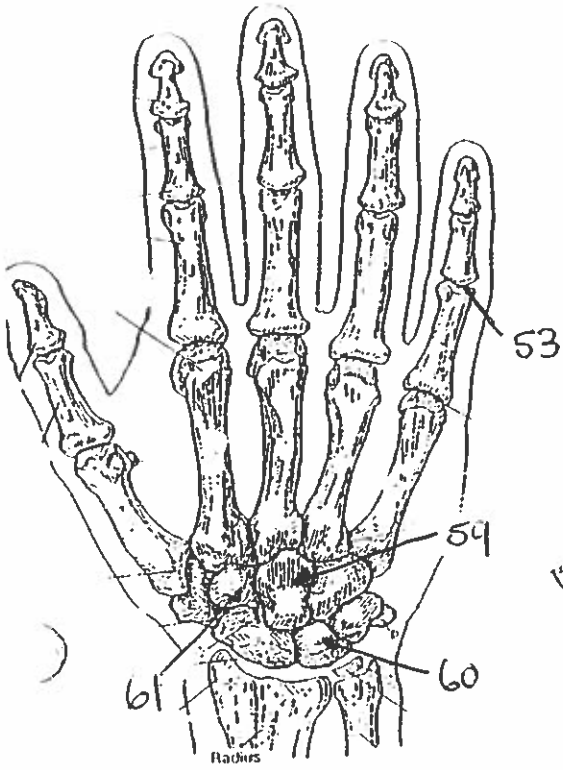




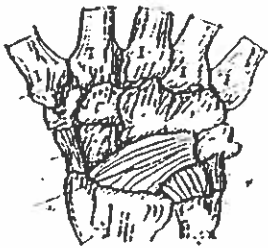
PECTORAL GIRDLE & ARM BONE HUMERUS.

FOREARM BONES

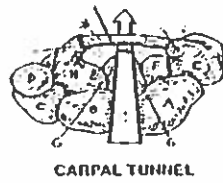




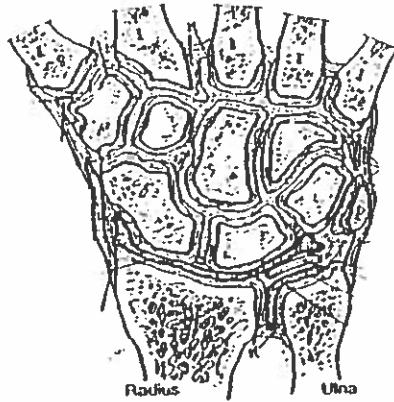
POSTERIOR (DORSAL) VIEW
(Right hand)



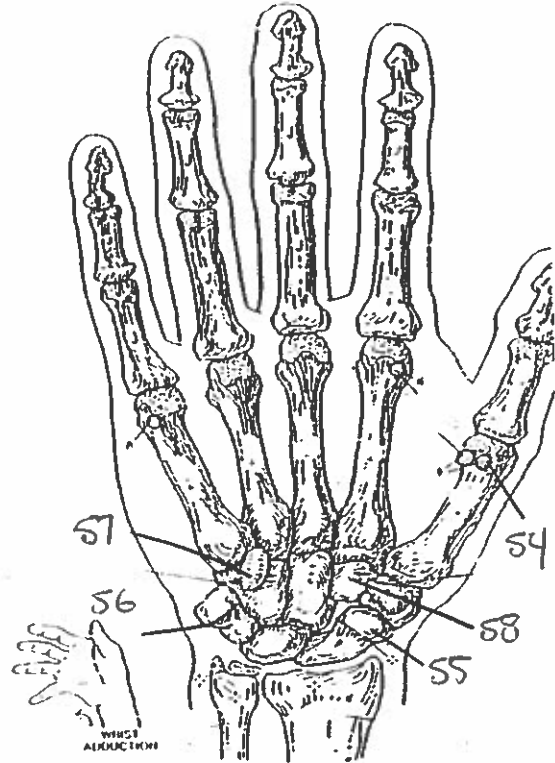
MAJOR LIGAMENTS



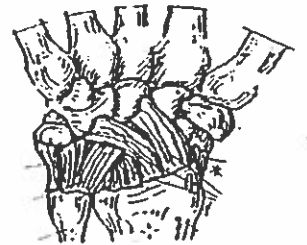CARPAL TUNNEL



JOINTS OF WRIST & CARPALS
(Dorsal view of frontal section)

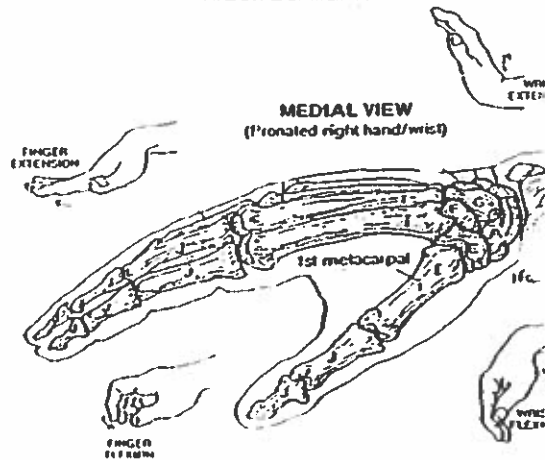


ANTERIOR (PALMAR) VIEW
(Right hand)



MAJOR LIGAMENTS

WRIST AND HAND BONES



MEDIAL VIEW
(Pronated right hand/wrist)

Quiz #1 Bones & Skull/Scapula (AL)

1. frontal bone
2. supraorbital foramen
3. zygomatic bone
4. maxilla bone
5. temporal bone.
6. body
7. mental foramen.
8. ramus
9. occipital bone.
10. mandible bone
11. maxilla bone
12. parietal bone
13. mastoid process
14. external auditory meatus.
15. glabella.
16. coronal suture.
17. sagittal suture.
18. lambdoidal suture
19. coronal suture.
20. frontal bone
21. occipital bone.
22. ~~mastoid process~~ temporal bone
23. mandible bone
24. occipital bone
25. mastoid process
26. occipital condyle
27. mandibular foramen.
28. manubrium bone
29. body of sternum
30. xiphoid process of sternum

31. true ribs
32. floating ribs
33. scapula
34. humerus
35. subscapular fossa
36. medial morym
37. coracoid process
38. acromion
39. head
40. deltoid tuberosity
41. lesser tubercle
42. coronoid fossa
43. trochlea
44. supraspinous fossa
45. infraspinous fossa
46. greater tubercle
47. lateral epicondyle
48. trochlea
49. olecranon fossa
50. humerus
51. ~~radius~~ radius
52. ~~radius~~ ulna.
53. phalanges
54. sesamoid bone.
55. scaphoid
56. pisiform
57. hamate
58. trapezoid
59. capitate
60. lunate
61. trapezoid.