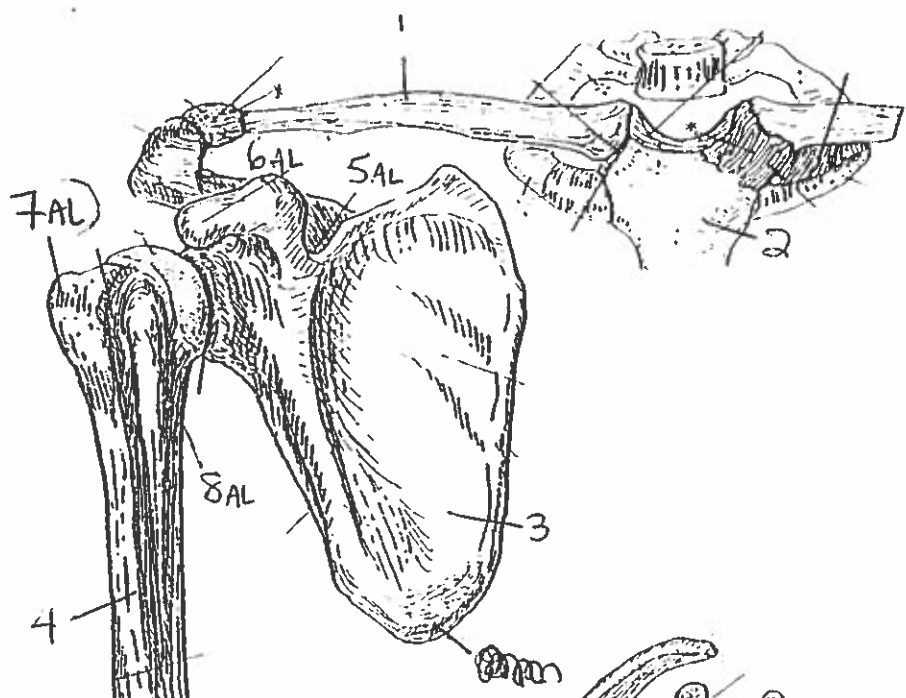
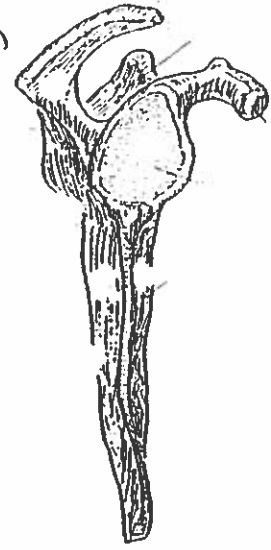


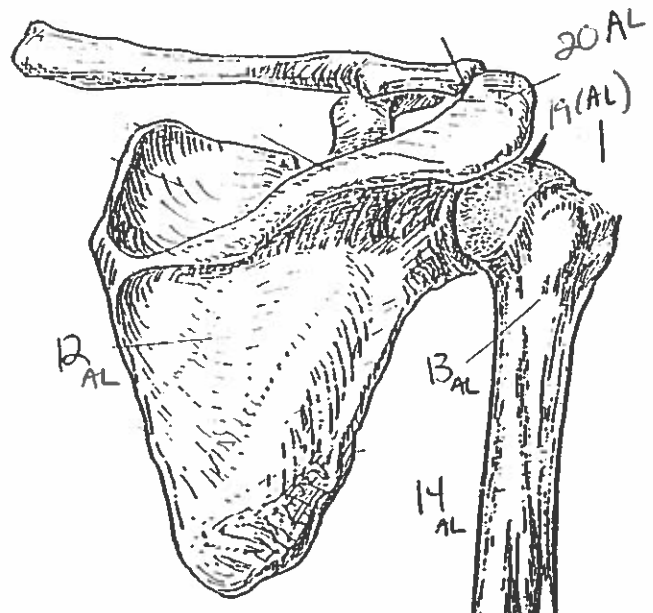
Quiz #2
Shoulder, Arm & Hand



ANTERIOR VIEW
(right arm)



LATERAL VIEW



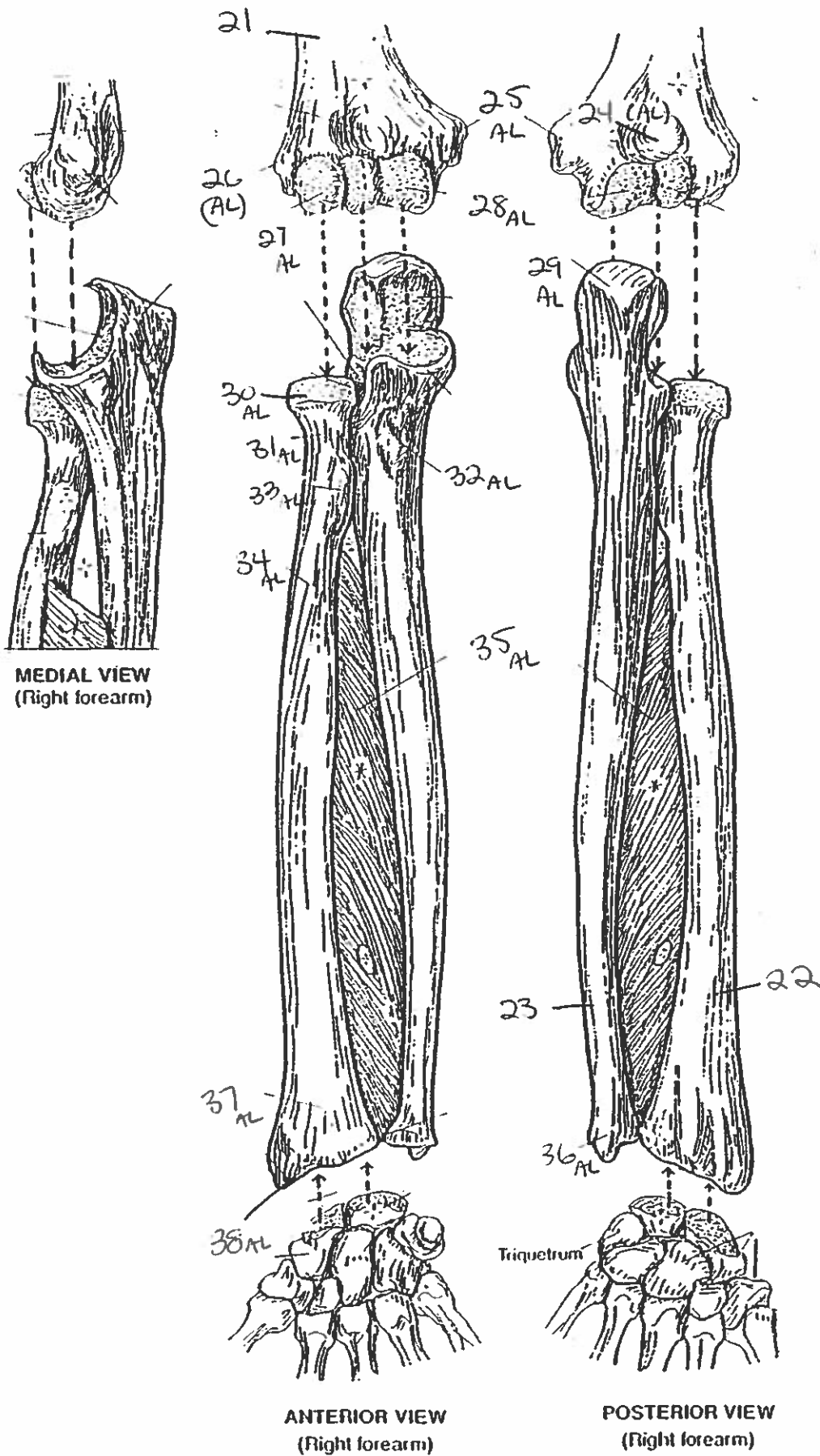
POSTERIOR VIEW

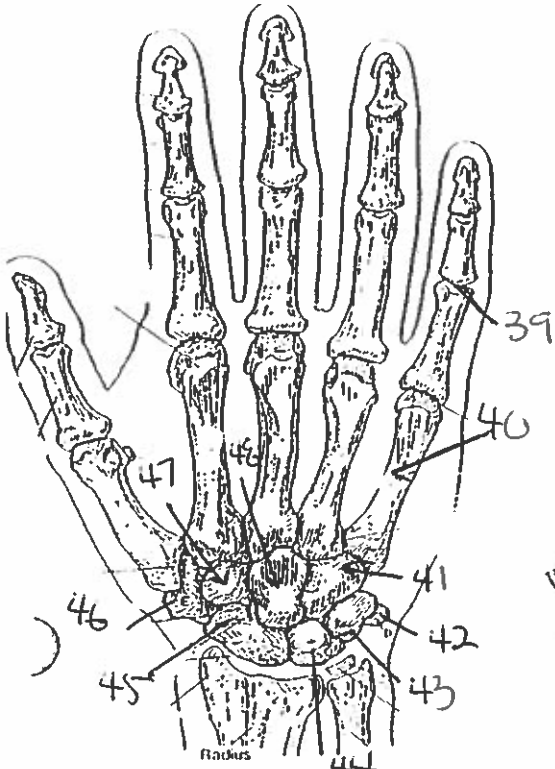
10AL
11AL

PECTORAL GIRDLE & ARM BONE
HUMERUS.

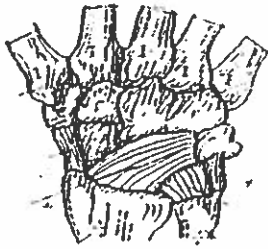
18AL
17AL
16A

FOREARM BONES

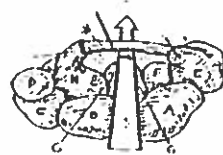




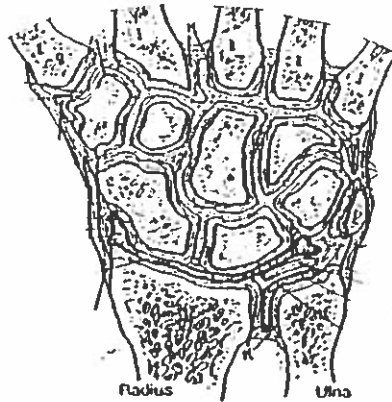
POSTERIOR (DORSAL) VIEW
(right hand)



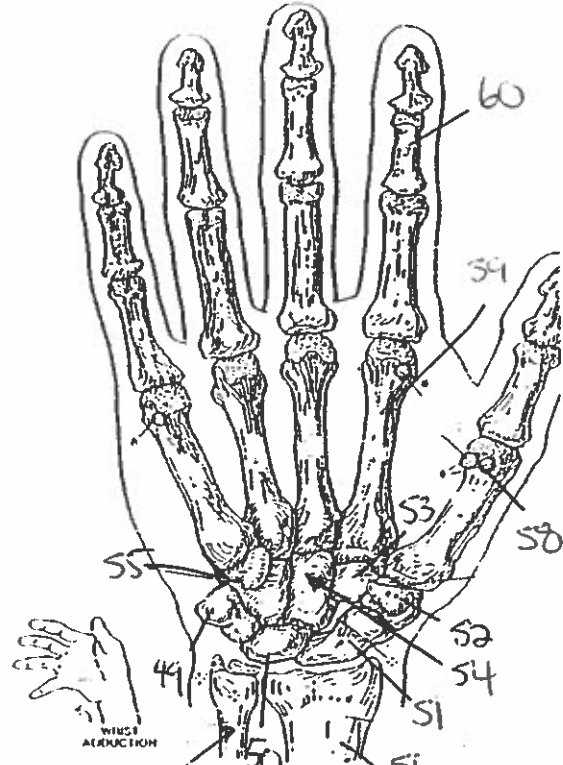
MAJOR LIGAMENTS



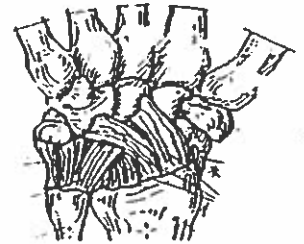CARPAL TUNNEL



JOINTS OF WRIST & CARPALS
(Dorsal view of frontal section)

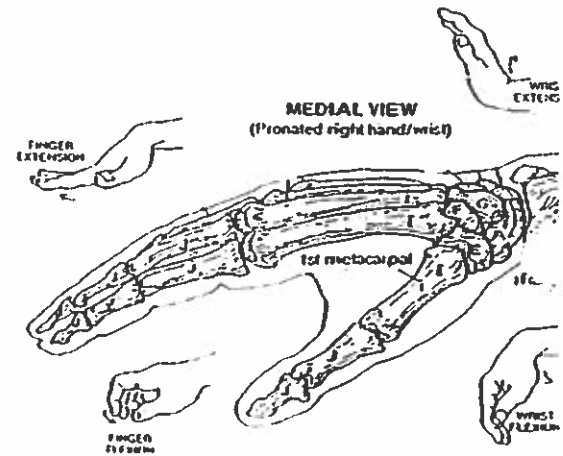


ANTERIOR (PALMAR) VIEW
(right hand)



MAJOR LIGAMENTS

WRIST AND HAND BONES



MEDIAL VIEW
(Pronated right hand/wrist)

Quiz #2: Shoulder, Arm & Hand,

1. clavicle
2. manubrium
3. scapula
4. humerus
5. superior notch
6. ~~acromion~~ coracoid process
7. greater tubercle
8. lesser tubercle
9. medial epicondyle
10. lateral epicondyle
11. capitulum
12. infraspinous fossa
13. surgical neck
14. shaft
15. deltoid tuberosity
16. lateral epicondyle
17. trochlea
18. medial epicondyle
19. head
20. acromion
21. humerus
22. radius
23. ulna
24. olecranon fossa
25. medial epicondyle
26. lateral epicondyle
27. capitulum
28. trochlea
29. olecranon
30. head

31. neck
32. ulna tuberosity
33. radial tuberosity
34. shaft
35. interosseous membrane
36. styloid process of ulna
37. ~~sty~~ wrist
38. styloid process of radius
39. phalanges
40. metacarpals
41. hamate
42. pisiform
43. triquetrum
44. lunate
45. scaphoid
46. trapezium
47. trapezoid
48. capitate
49. pisiform
50. lunate
51. scaphoid
52. trapezium
53. trapezoid
54. capitate
55. hamate
56. radius
57. ulna
58. sesamoid
59. metacarpal
60. phalanges