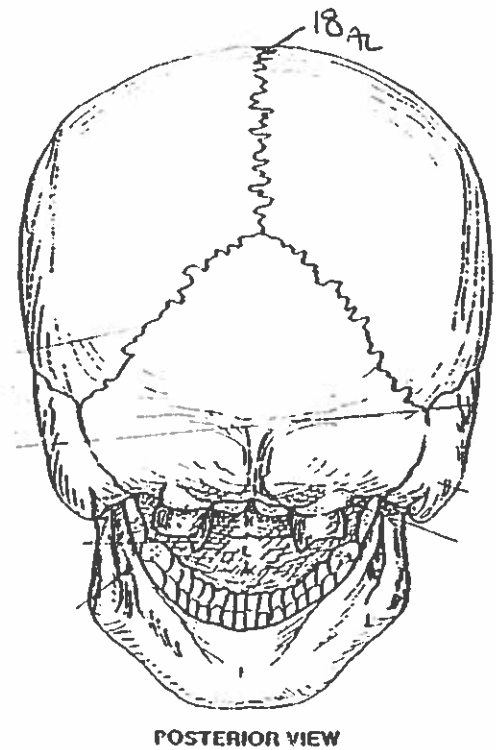
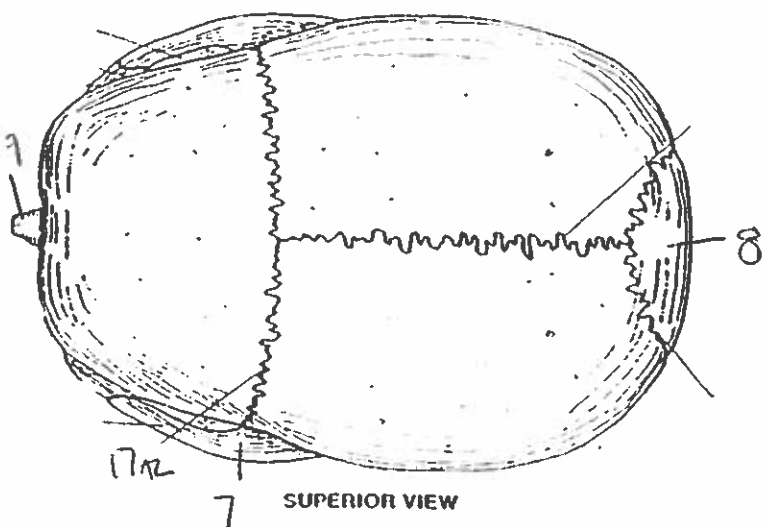
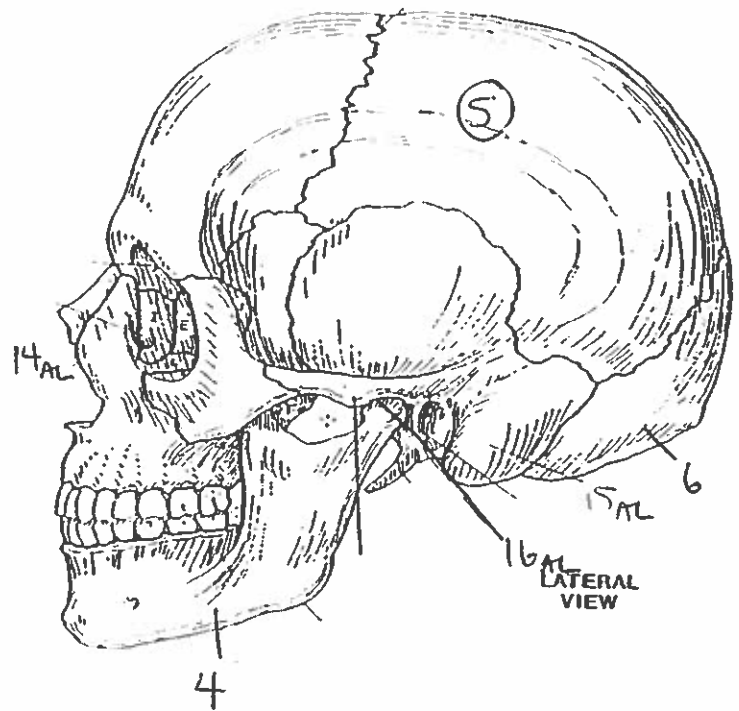
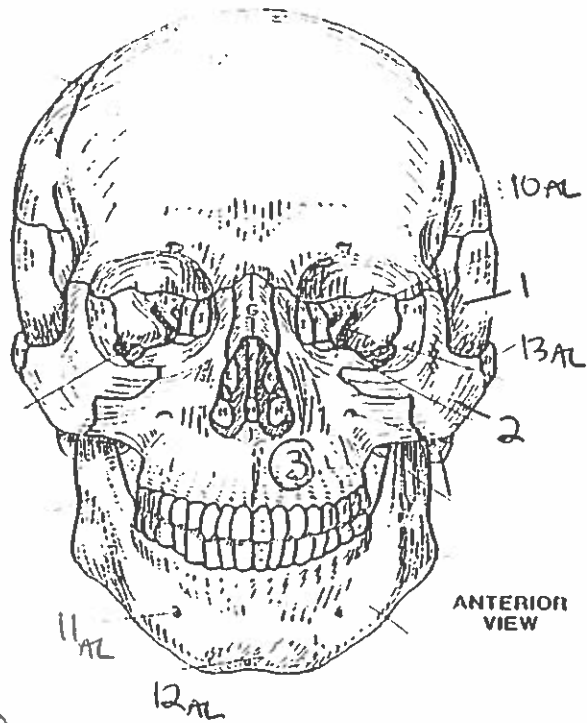
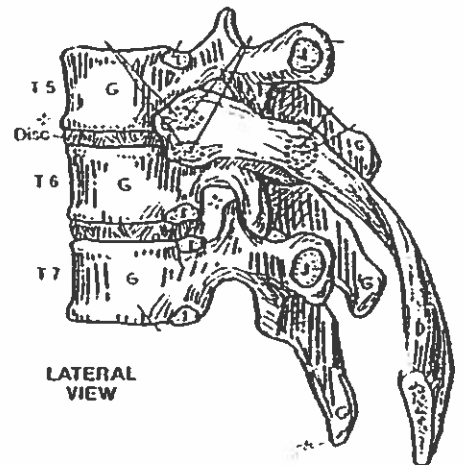
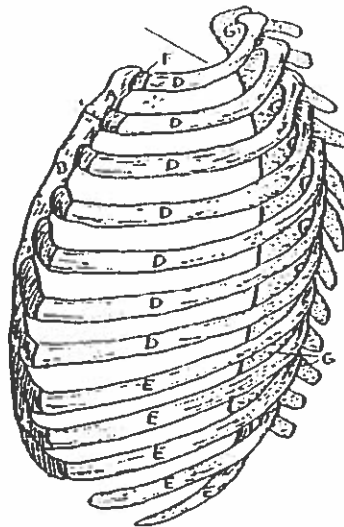
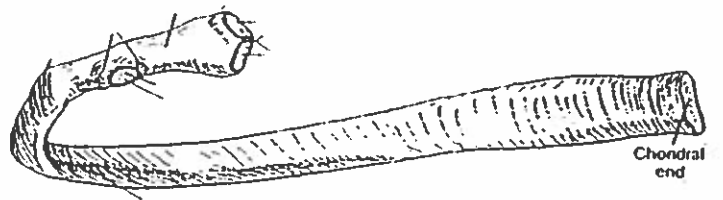
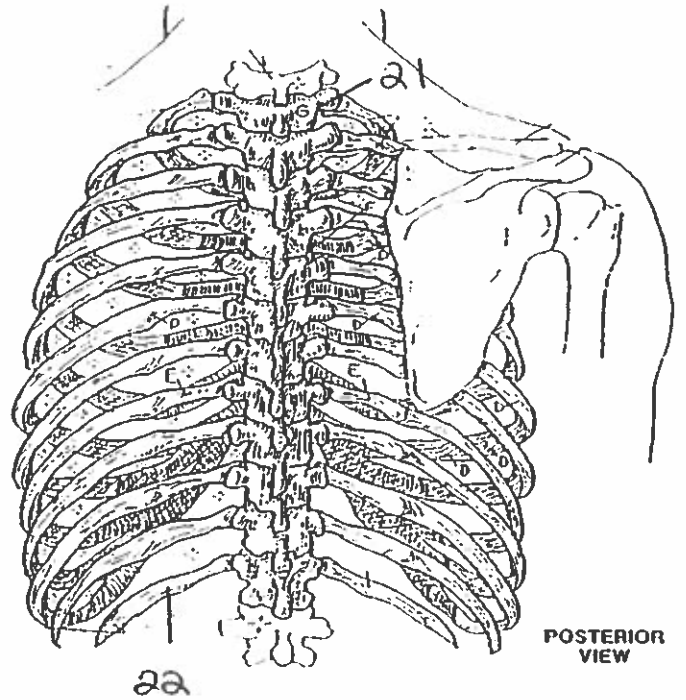
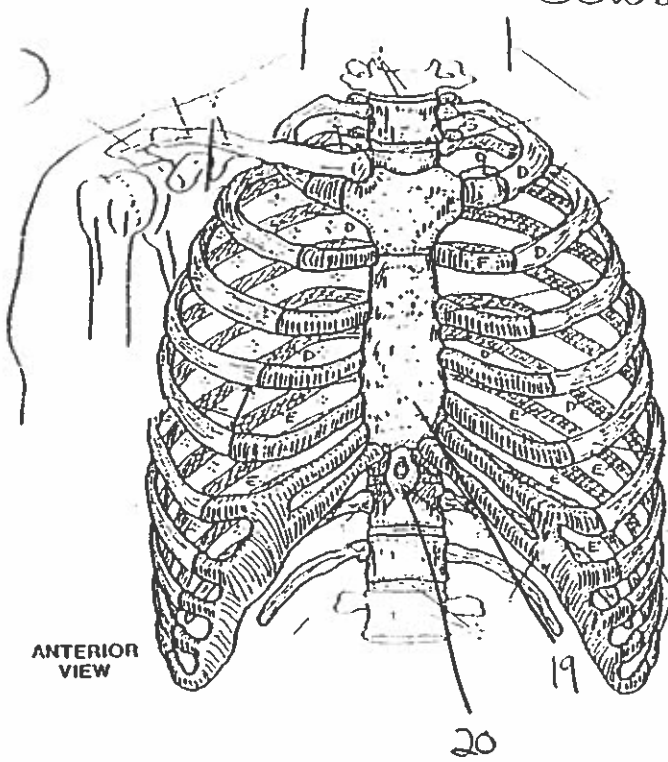
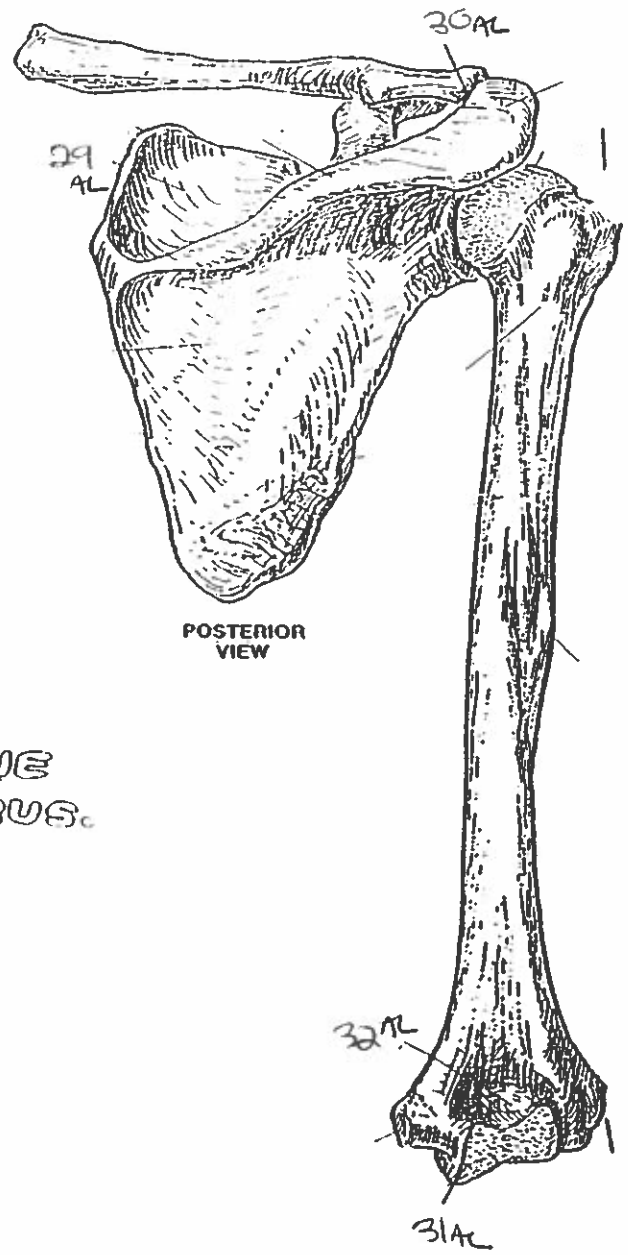
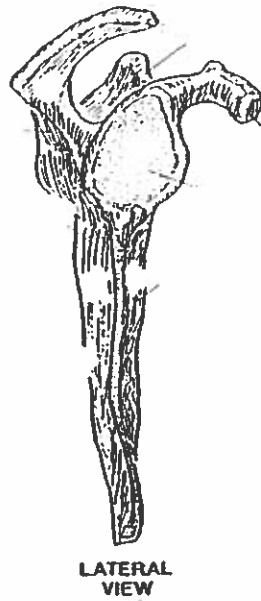
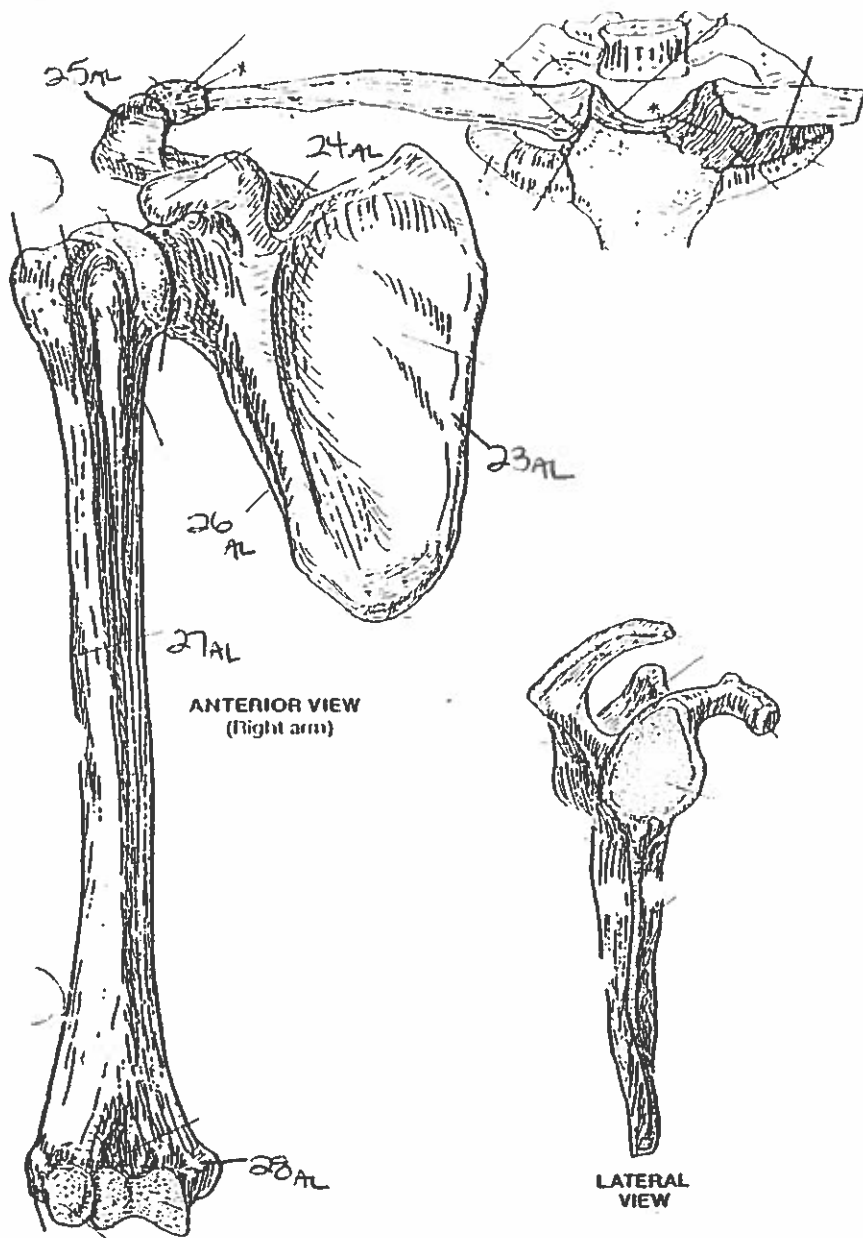


BONES OF THE SKULL



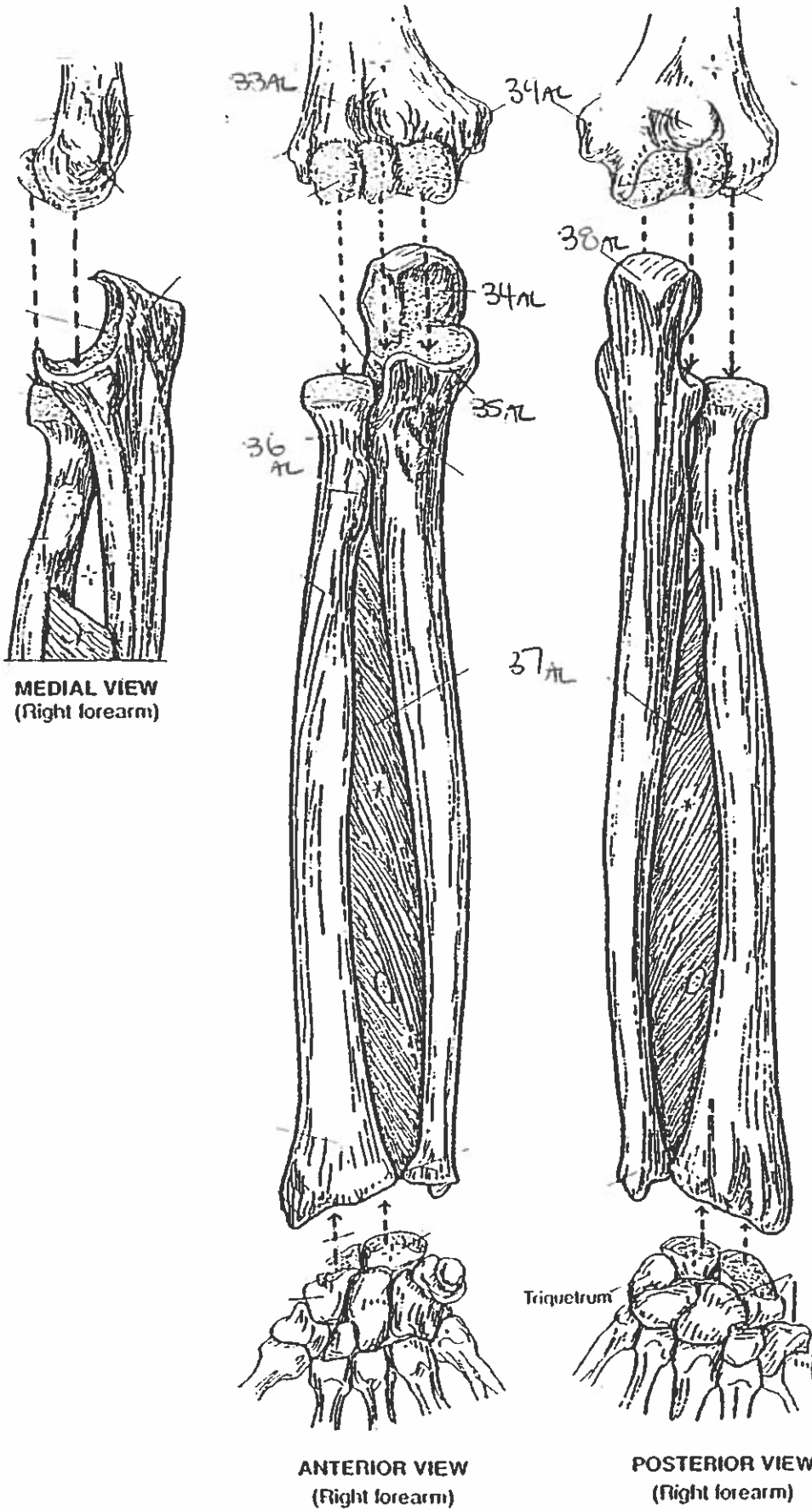
BONY THORAX

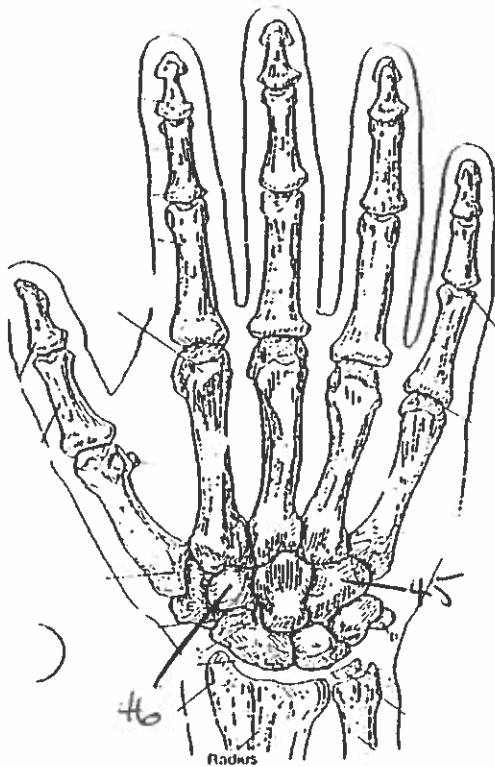




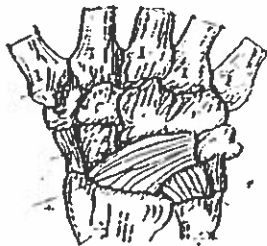
PECTORAL GIRDLE & ARM BONE
HUMERUS.

FOREARM BONES

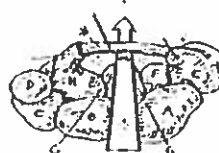



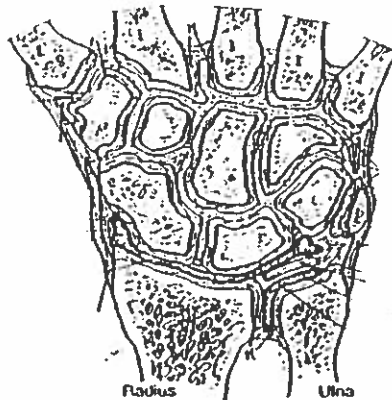
POSTERIOR (DORSAL) VIEW
(Right hand)



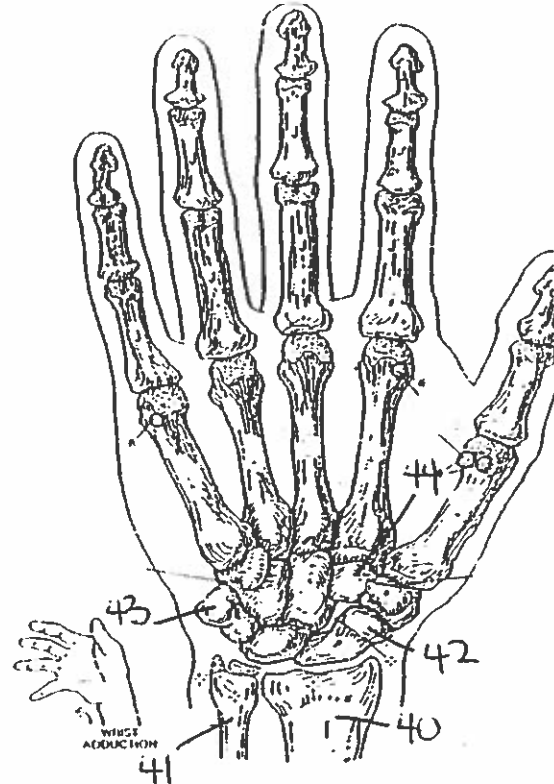
MAJOR LIGAMENTS



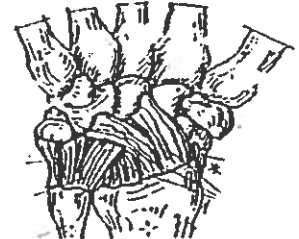CARPAL TUNNEL



JOINTS OF WRIST & CARPALS
(Dorsal view of frontal section)

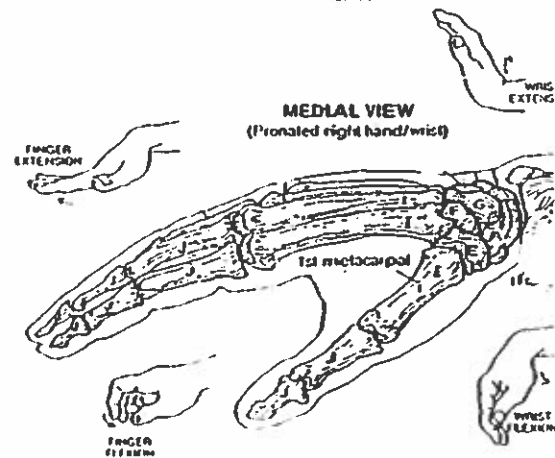


ANTERIOR (PALMAR) VIEW
(Right hand)



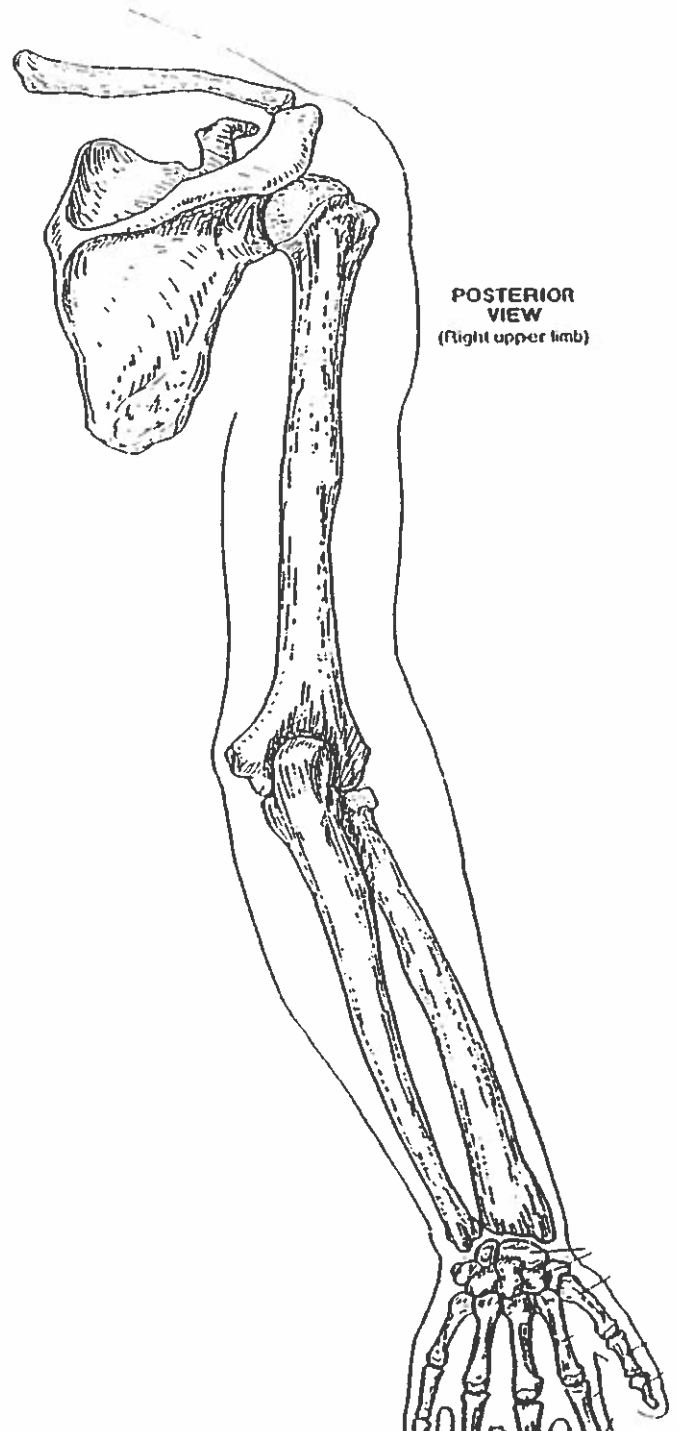
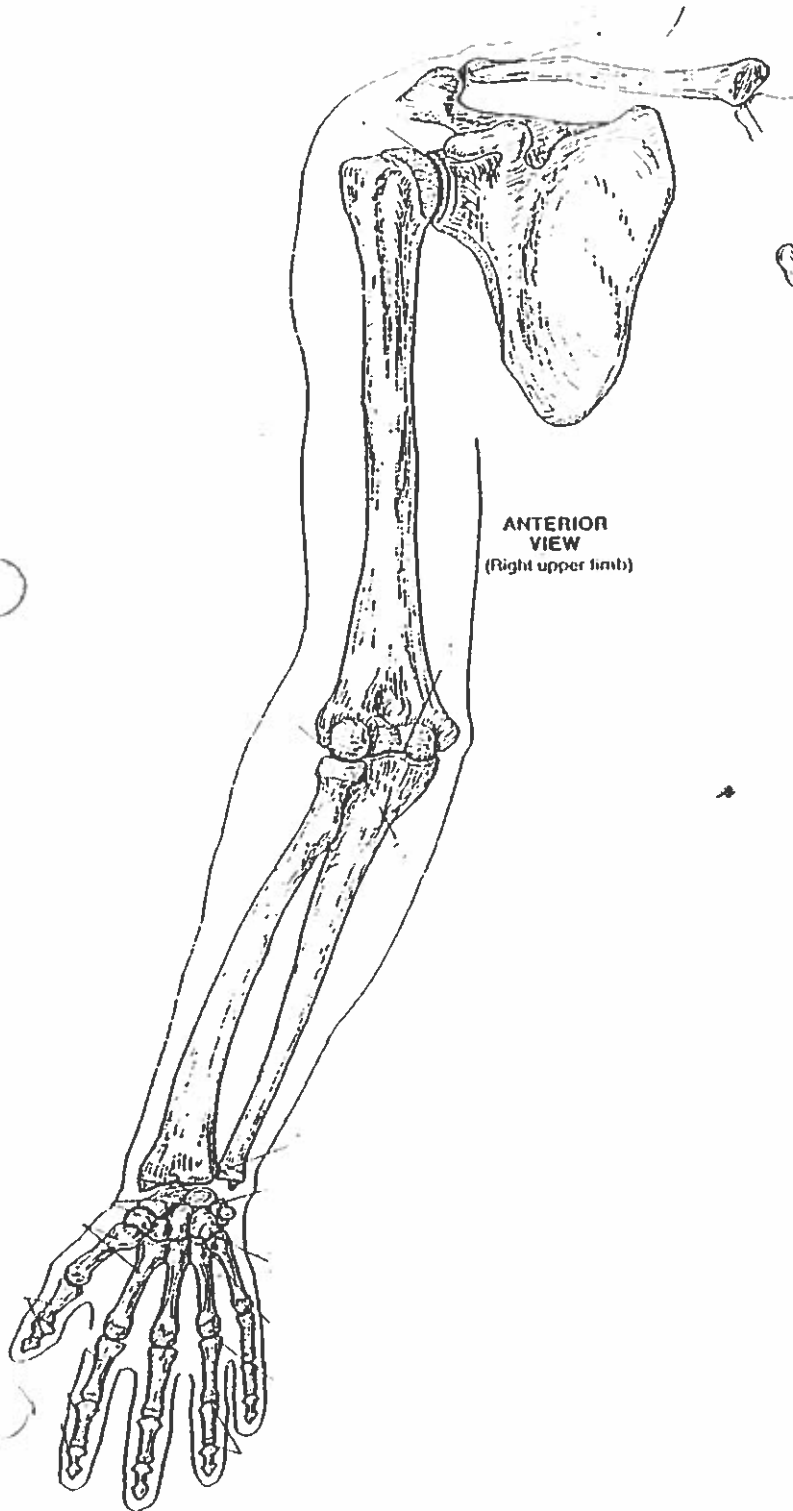
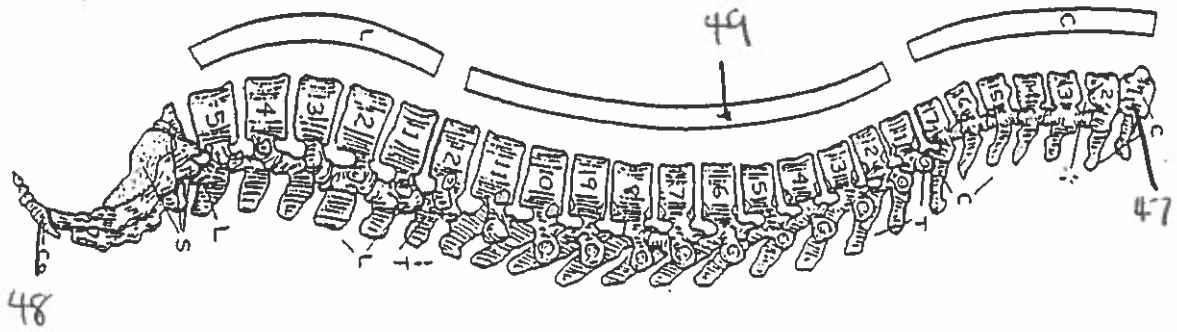
MAJOR LIGAMENTS

WRIST AND HAND BONES



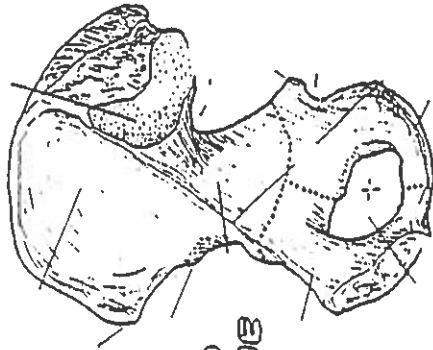
MEDIAL VIEW
(Pronated right hand/wrist)

VERTEBRAL COLUMN

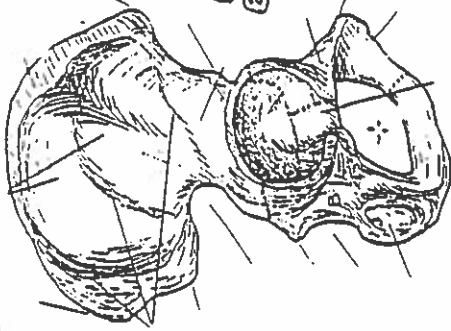


HIP BONE, PELVIC GIRDLE, & PELVIS

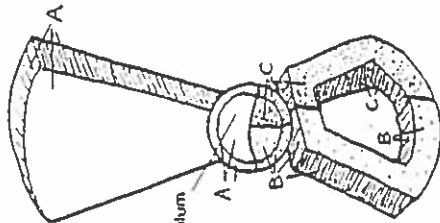
MEDIAL VIEW
(Right bone)



LATERAL VIEW
(Right bone)



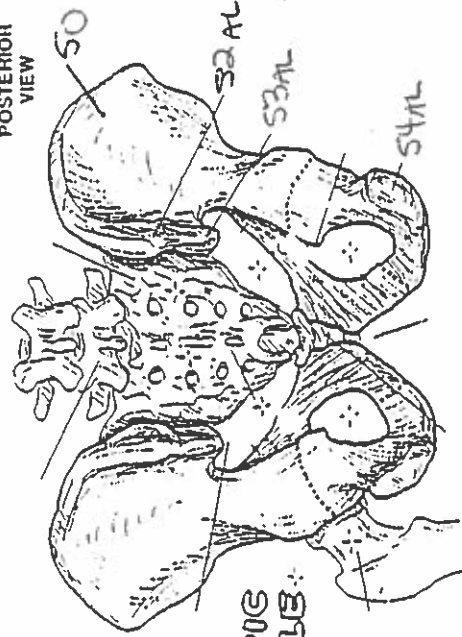
HIP BONE



LATERAL VIEW
(Diagrammatic)

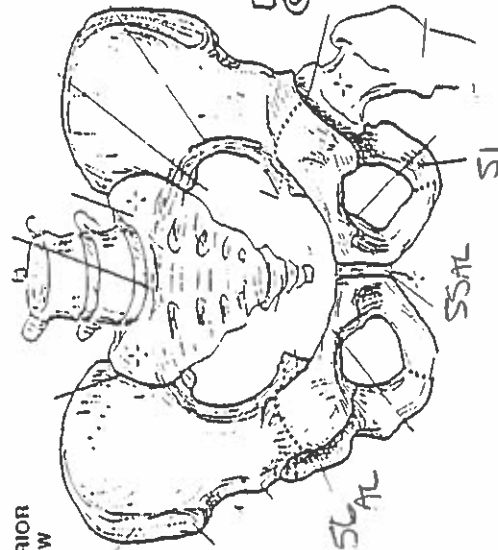
Acetabulum

POSTERIOR VIEW

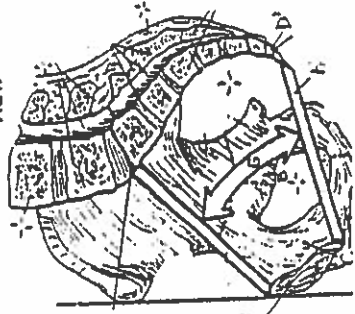


PELVIC GIRDLE

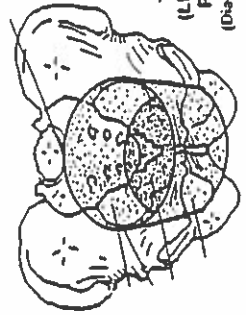
ANTERIOR VIEW



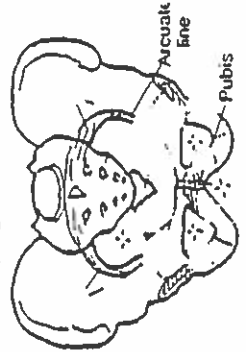
MEDIAL/SAGITTAL VIEW



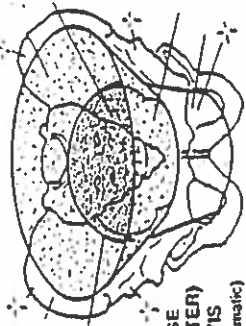
TRUE (LESSER) PELVIS
(Diagrammatic)



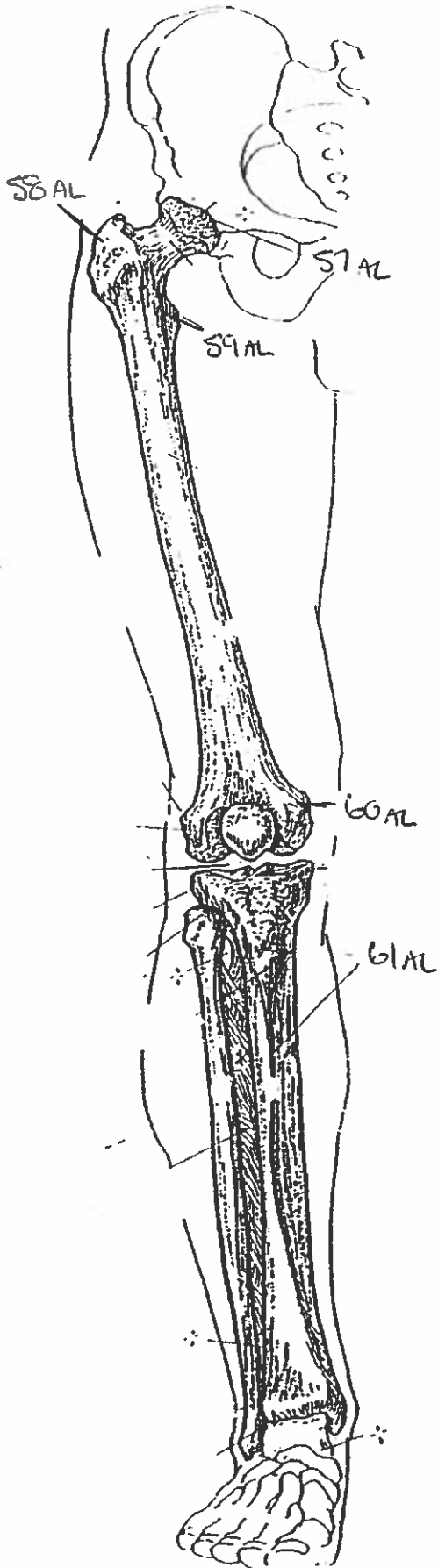
PELVIS



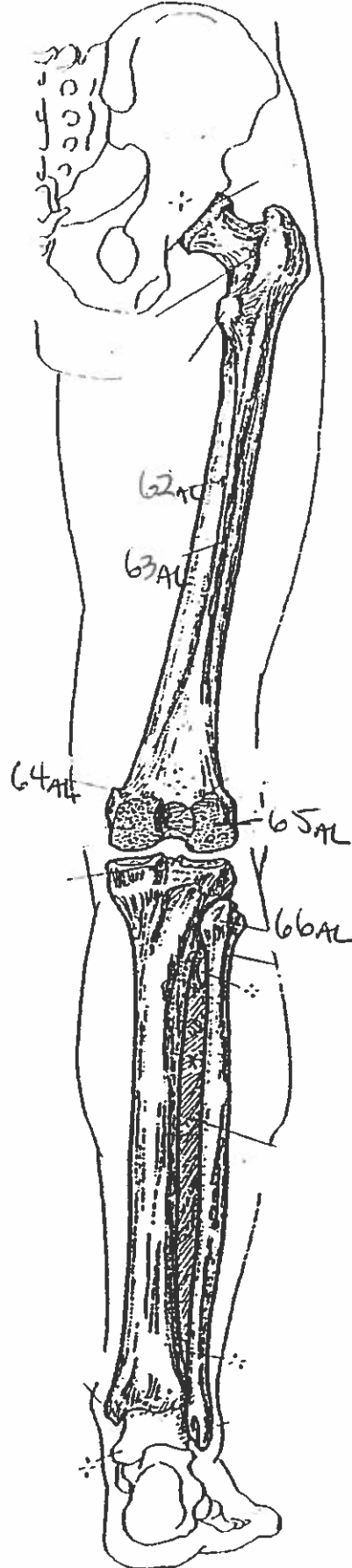
FALSE (GREATER) PELVIS
(Diagrammatic)



ANTERIOR VIEW
(Right limb)

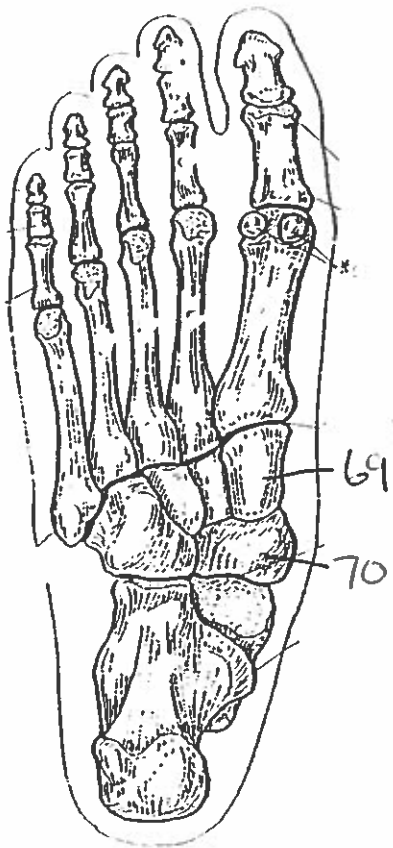
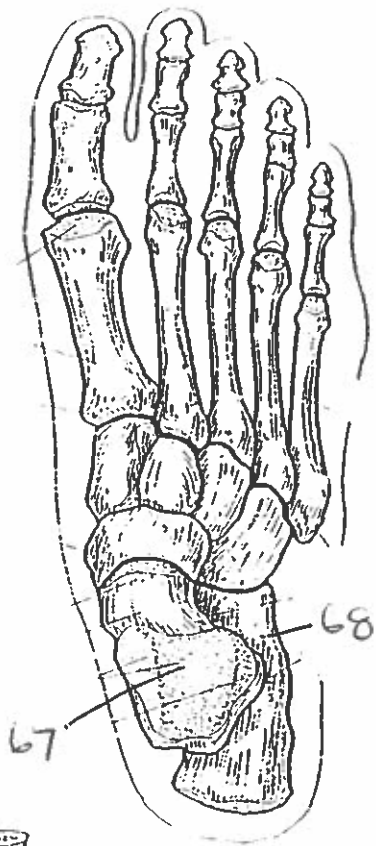
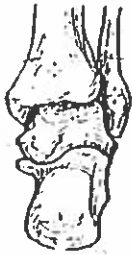

POSTERIOR VIEW
(Right limb)

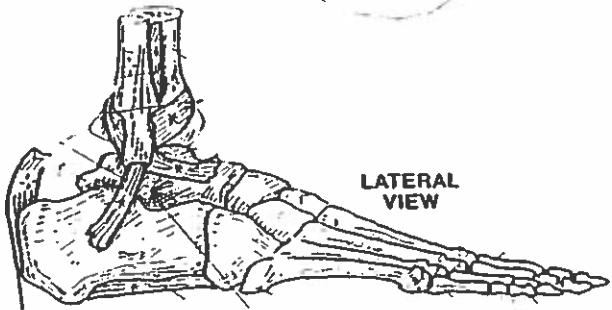
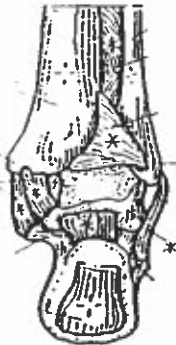

THIGH & LEG BONES

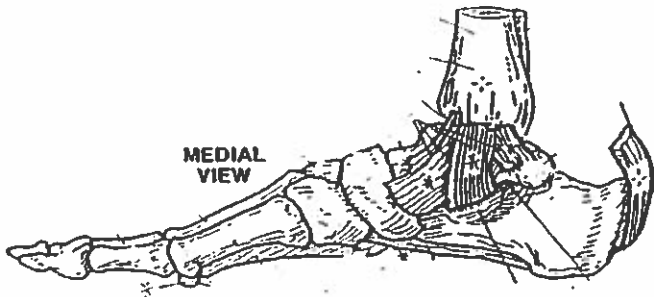
ANKLE & FOOT BONES



POSTERIOR
VIEW



LATERAL
VIEW



MEDIAL
VIEW

Quiz #6: All Bones & Landmarks.

1. temporal bone
2. zygomatic bone
3. maxilla bone
4. mandible bone
5. parietal bone
6. occipital bone
7. temporal bone
8. occipital bone
9. nasal bone
10. supraorbital foramen
11. mental foramen
12. mental protuberance.
13. zygomatic arch
14. nasal cavity.
15. mastoid process
16. temporomandibular joint
17. coronal suture
18. sagittal suture
19. body
20. xiphoid process
21. axis
22. floating ribs
23. medial margin
24. superior notch
25. acromion
26. lateral margin
27. deltoid tuberosity
28. medial epicondyle.
29. supraspinous fossa
30. acromioclavicular joint
31. trochlea
32. olecranon fossa
33. coronoid fossa
34. trochlear notch
35. coronoid fossa

36. neck
37. interosseous membrane
38. olecranon
39. medial epicondyle
40. radius
41. ulna
42. scaphoid
43. ~~trapezoid~~ pisiform
44. trapezoid
45. hamate
46. trapezoid
47. atlas
48. coccyx
49. thoracic vertebra
50. ilium
51. ischium
52. posterior superior iliac spine
53. posterior inferior iliac spine
54. ischial tuberosity
55. symphysis pubis
56. acetabulum
57. acetabulum
58. greater trochanter
59. lesser trochanter
60. medial epicondyle
61. anterior border
62. nutrient foramen
63. linea aspera
64. adductor tubercle
65. lateral condyle
66. head
67. talus
68. calcaneus
69. cuneiform
70. navicular.