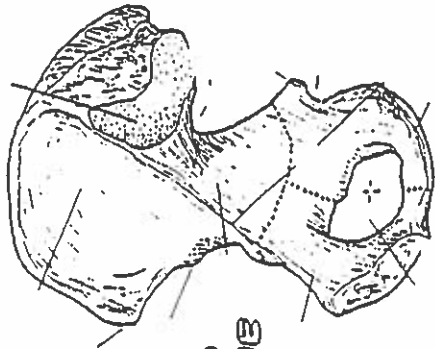


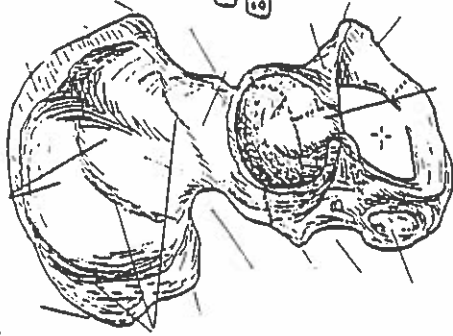
HIP BONE, PELVIC GIRDLE, & PELVIS

Quiz #8 Lower body Landmarks.

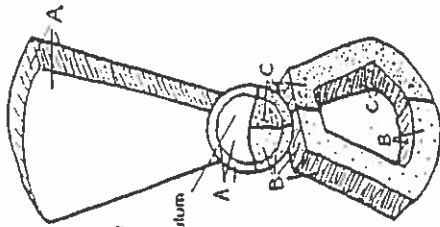
MEDIAL VIEW
(right bone)



LATERAL VIEW
(right bone)



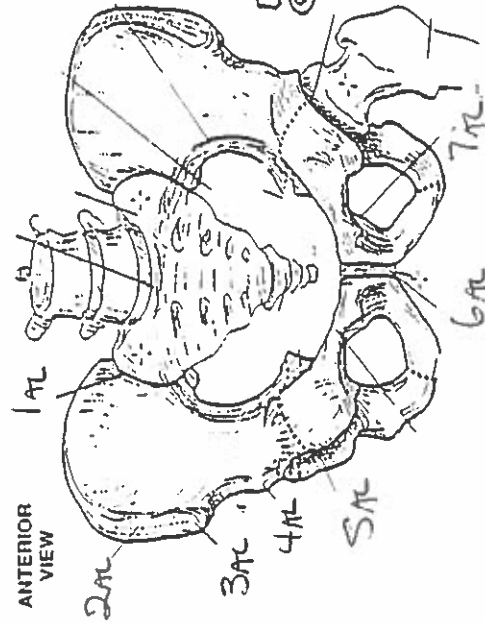
HIP BONE



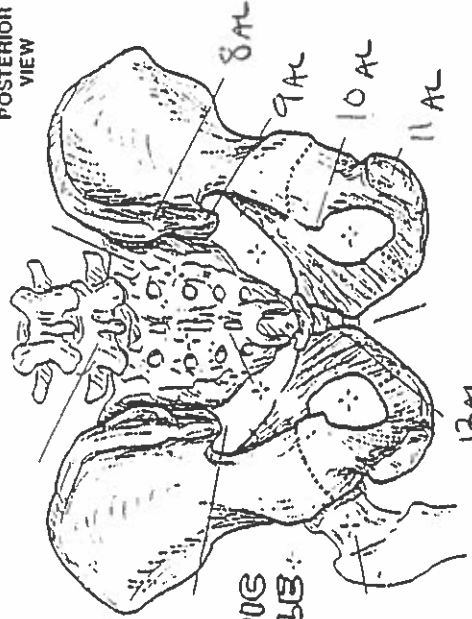
LATERAL VIEW
(Diagrammatic)

Acetabulum

ANTERIOR VIEW

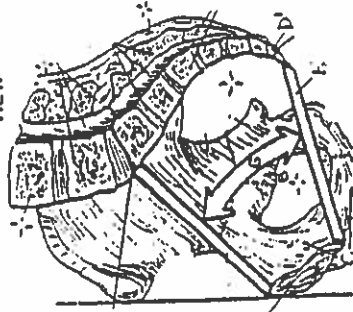


POSTERIOR VIEW

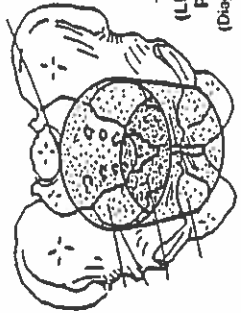


PELVIC GIRDLE

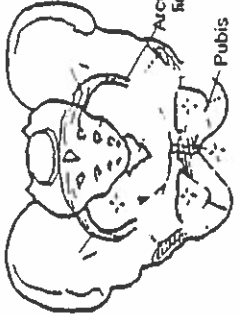
MEDIAL/SAGITTAL VIEW



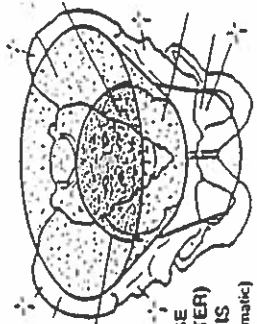
TRUE (LESSER) PELVIS
(Diagrammatic)



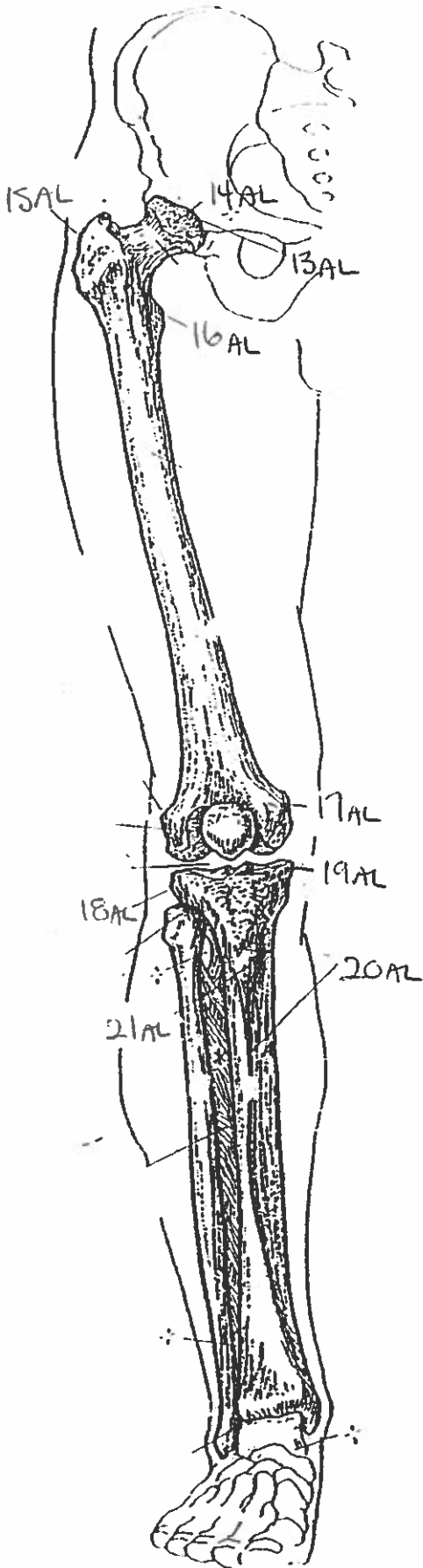
PELVIS



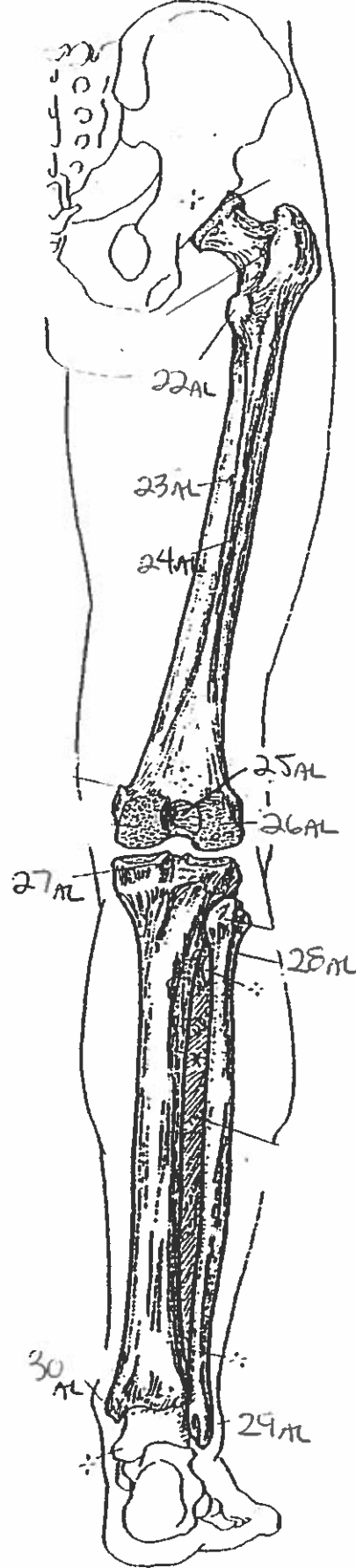
FALSE (GREATER) PELVIS
(Diagrammatic)



ANTERIOR VIEW
(Right limb)



POSTERIOR VIEW
(Right limb)



THIGH & LEG BONES

Quiz #8: Lower body Landmarks.

1. sacroiliac joint
2. iliac crest
3. anterior superior iliac spine.
4. anterior inferior iliac spine
5. acetabulum
6. symphysis pubis
7. pubic tubercle.
8. posterior superior iliac spine
9. posterior inferior iliac spine.
10. ischial spine
11. ischial tuberosity
12. coccyx
13. acetabulum
14. head
15. greater trochanter
16. lesser trochanter
17. medial epicondyle
18. lateral epicondyle
19. medial epicondyle
20. anterior border
21. fibial tuberosity.
22. lesser trochanter
23. nutrient foramen
24. linea aspera
25. intercondylar fossa
26. lateral condyle
27. intercondylar eminence
28. neck
29. lateral malleolus
30. medial malleolus