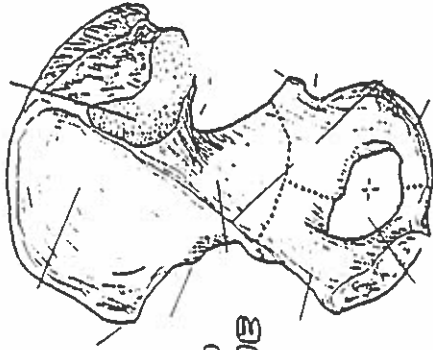


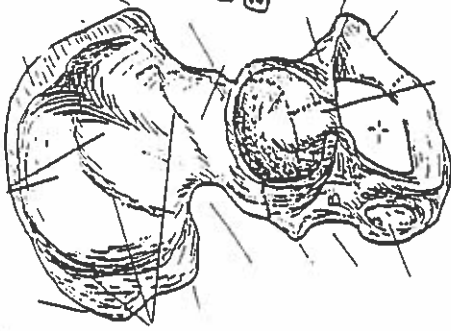
Quiz #3: Lower Body

HIP BONE, PELVIC GIRDLE, & PELVIS

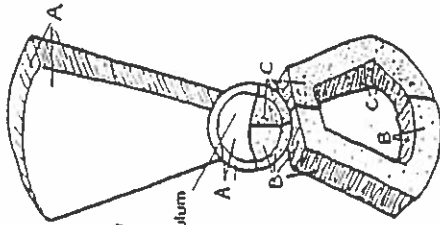
MEDIAL VIEW
(Right bone)



LATERAL VIEW
(Right bone)



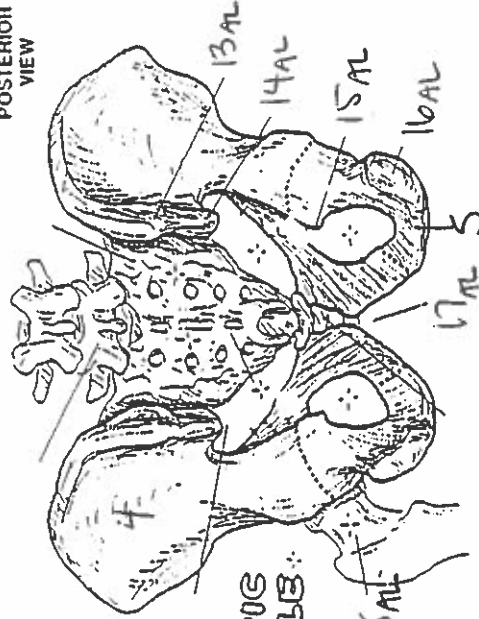
HIP BONE



LATERAL VIEW
(Diagrammatic)

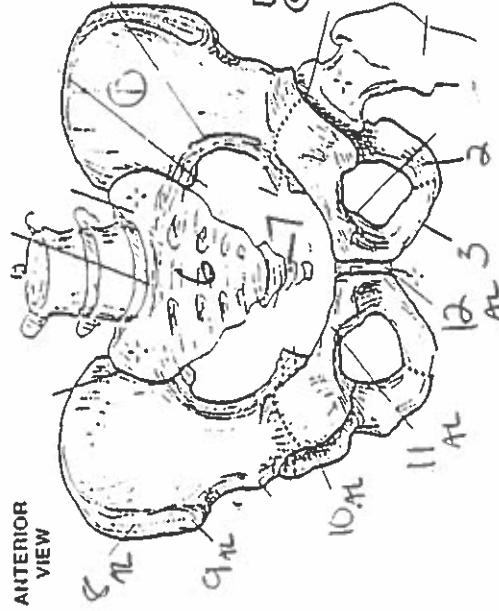
Acetabulum

POSTERIOR VIEW

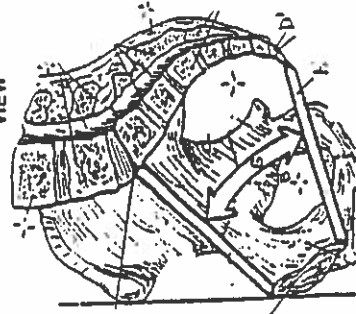


PELVIC GIRDLE

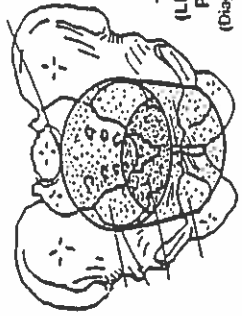
ANTERIOR VIEW



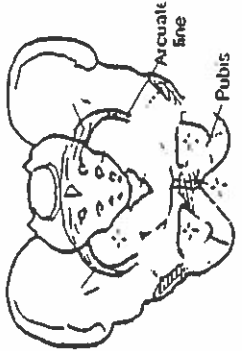
MEDIAL/SAGITTAL VIEW



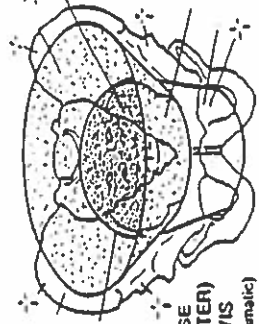
TRUE (LESSER) PELVIS
(Diagrammatic)



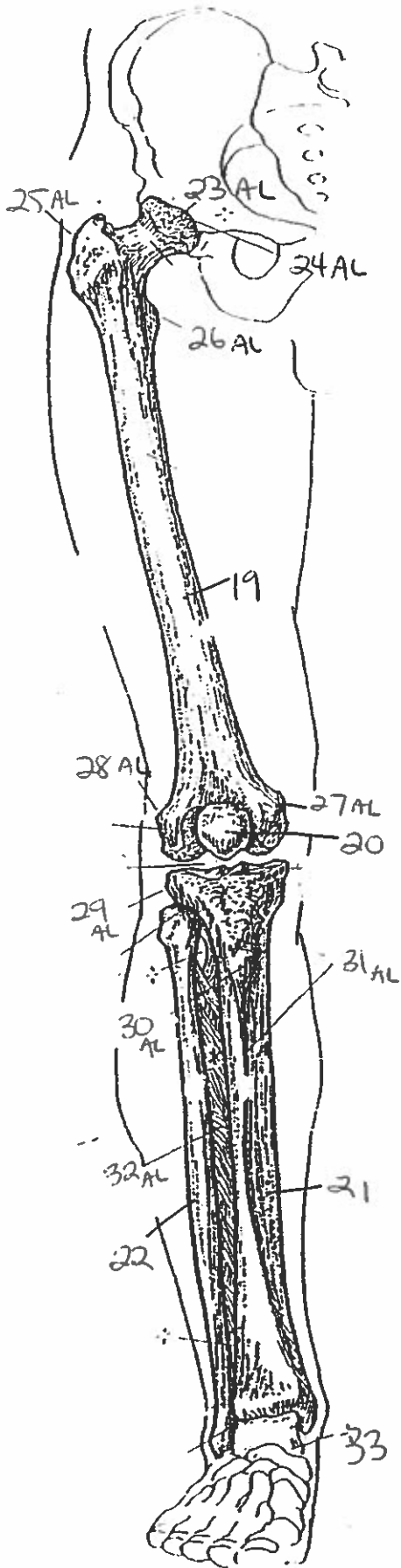
PELVIS



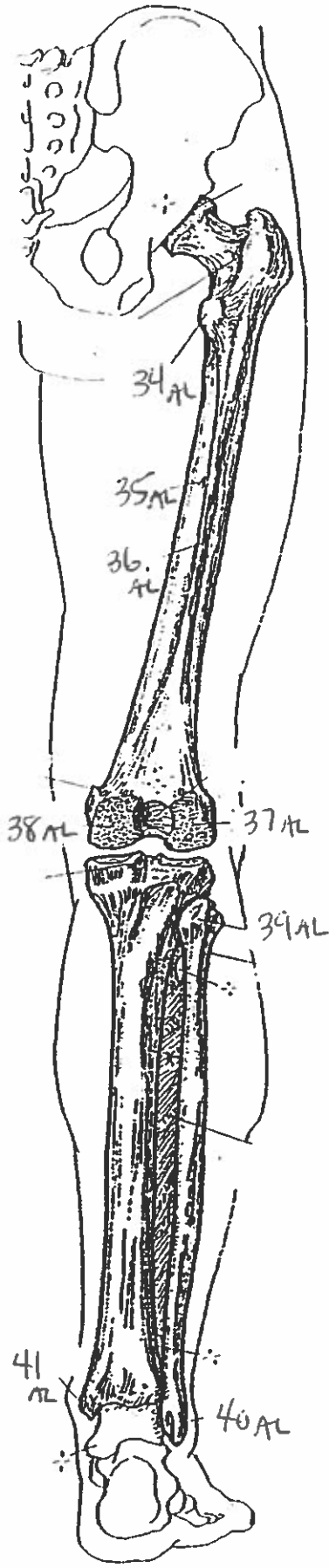
FALSE (GREATER) PELVIS
(Diagrammatic)



ANTERIOR VIEW
(flight limb)

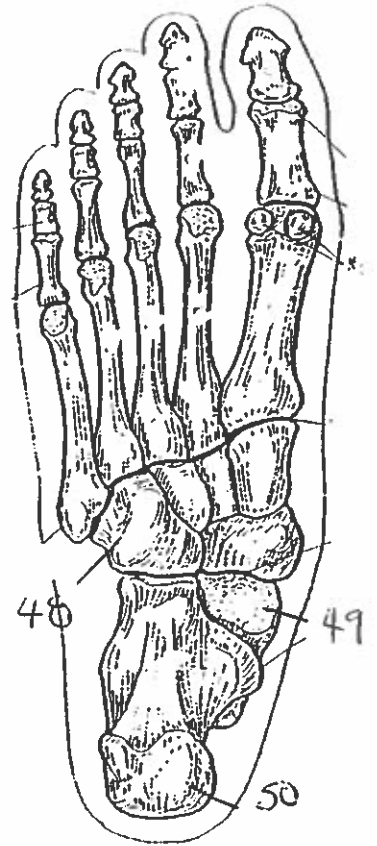
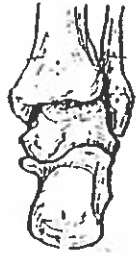
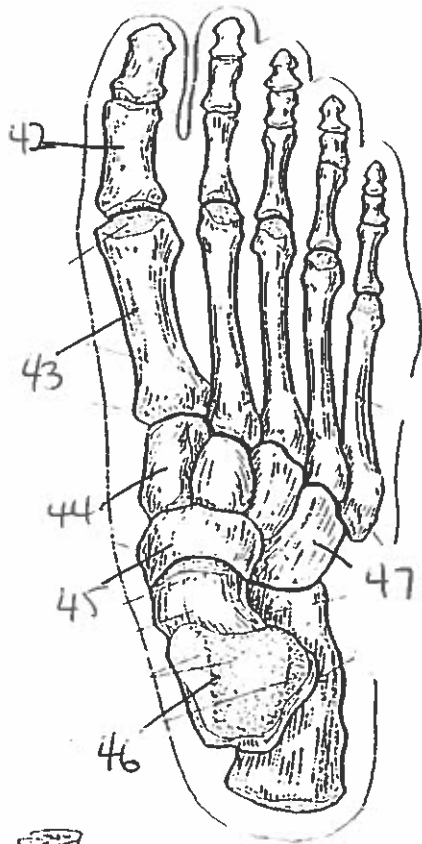


POSTERIOR VIEW
(flight limb)

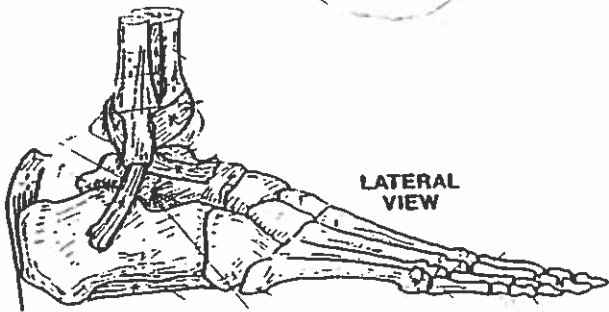
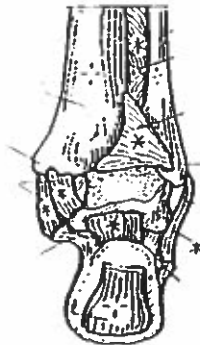

THIGH & LEG BONES

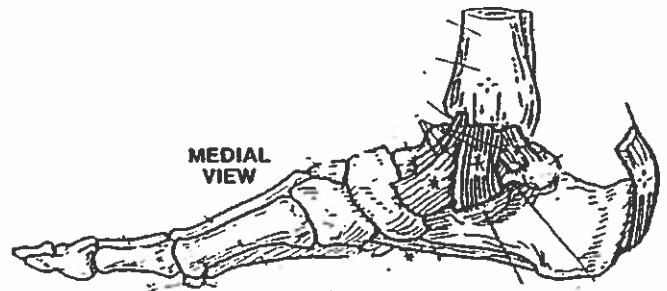
ANKLE & FOOT BONES



POSTERIOR VIEW



LATERAL VIEW



MEDIAL VIEW

- 1. ilium
- 2. ischium
- 3. pubis
- 4. ilium
- 5. ischium
- 6. sacrum
- 7. coccyx.
- 8. iliac crest
- 9. anterior ~~superior~~ ^{superior} iliac spine.
- 10. acetabulum
- 11. superior pubic ramis
- 12. symphysis pubis
- 13. posterior superior iliac spine
- 14. posterior inferior iliac spine
- 15. ischial spine
- 16. ischial tuberosity
- 17. subpubic angle.
- 18. neck
- 19. femur
- 20. patella
- 21. tibia
- 22. fibula.
- 23. head
- 24. acetabulum
- 25. greater trochanter
- 26. lesser trochanter
- 27. medial epicondyle
- 28. lateral epicondyle
- 29. lateral epicondyle
- 30. tibial tuberosity

- 31. anterior border
- 32. interosseous membrane
- 33. talus
- 34. lesser trochanter
- 35. nutrient foramen
- 36. linea aspera
- 37. lateral condyle
- 38. medial condyle
- 39. head
- 40. lateral malleolus
- 41. medial malleolus
- 42. phalanges
- 43. metatarsals
- 44. cuneiform
- 45. navicular
- 46. talus
- 47. cuboid
- 48. cuboid
- 49. talus
- 50. calcaneus