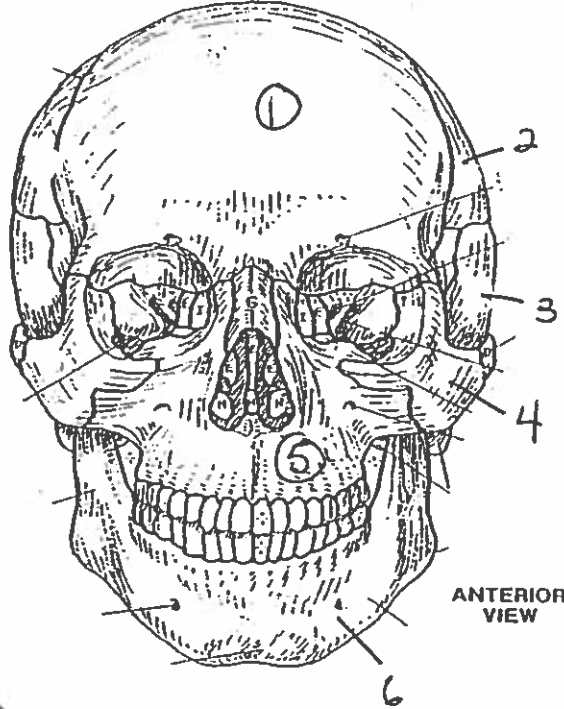
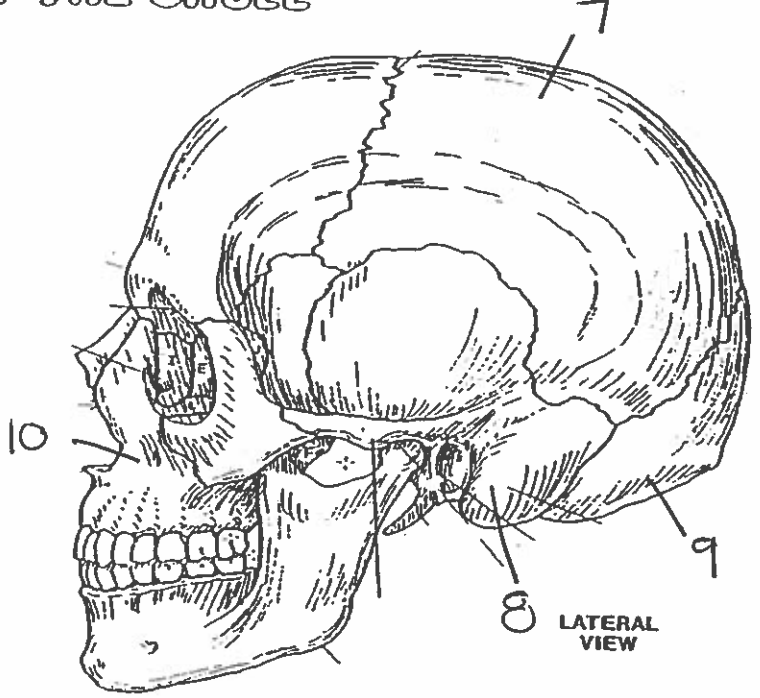


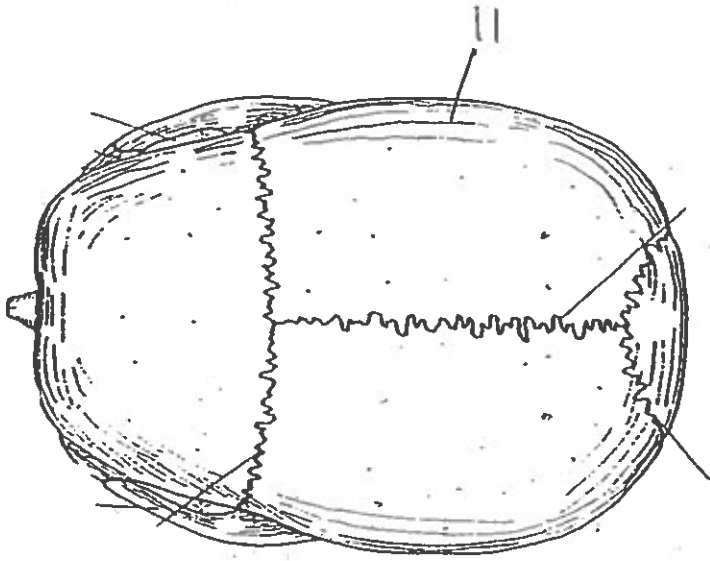
BONES OF THE SKULL



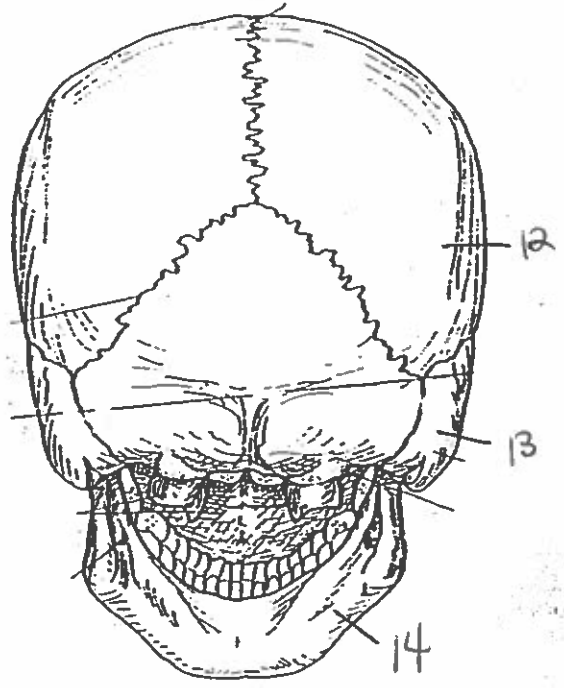
ANTERIOR VIEW



LATERAL VIEW

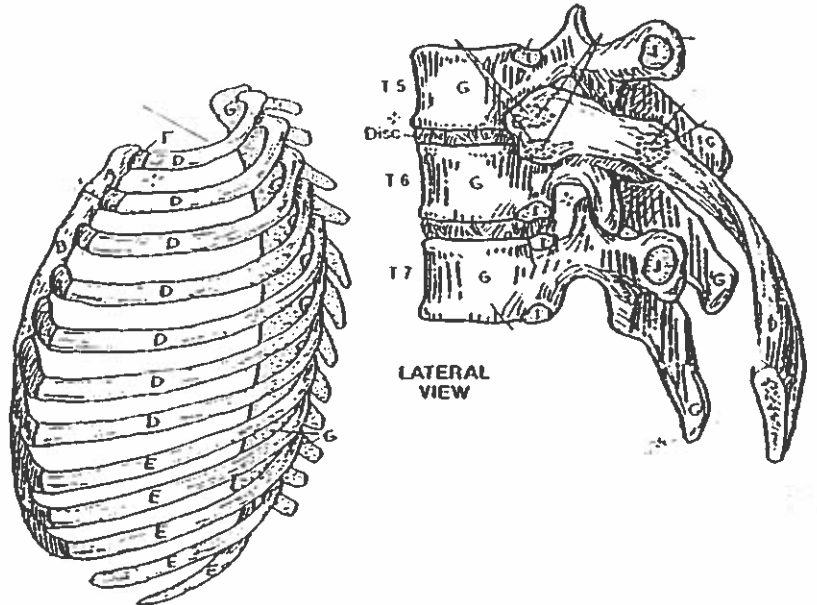
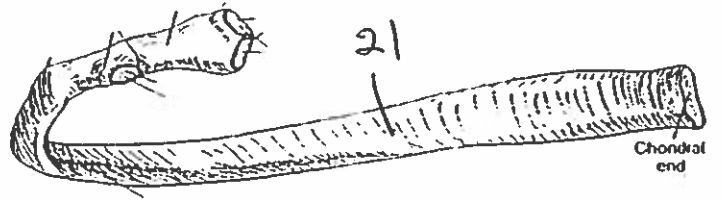
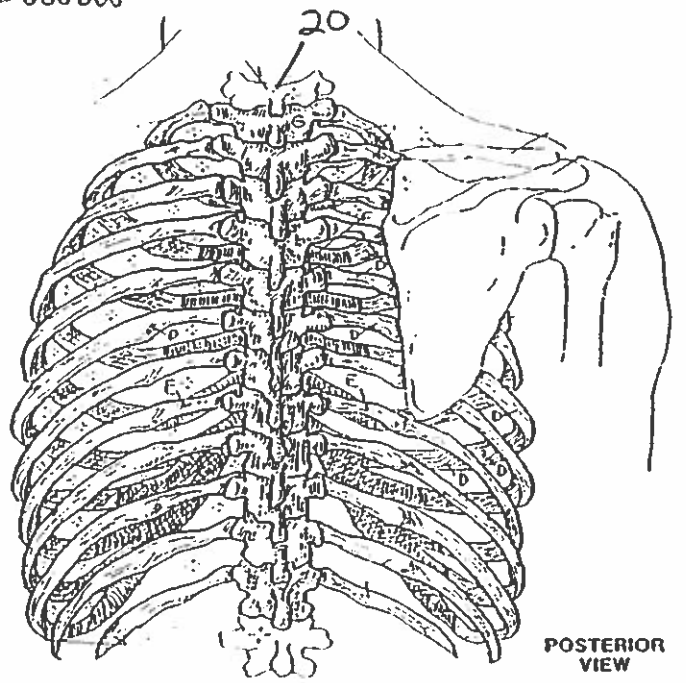
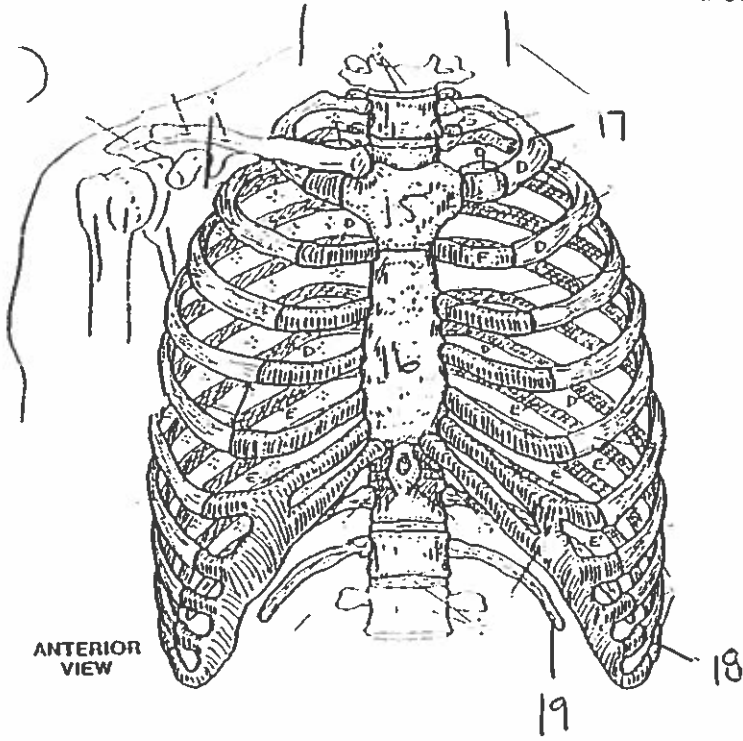


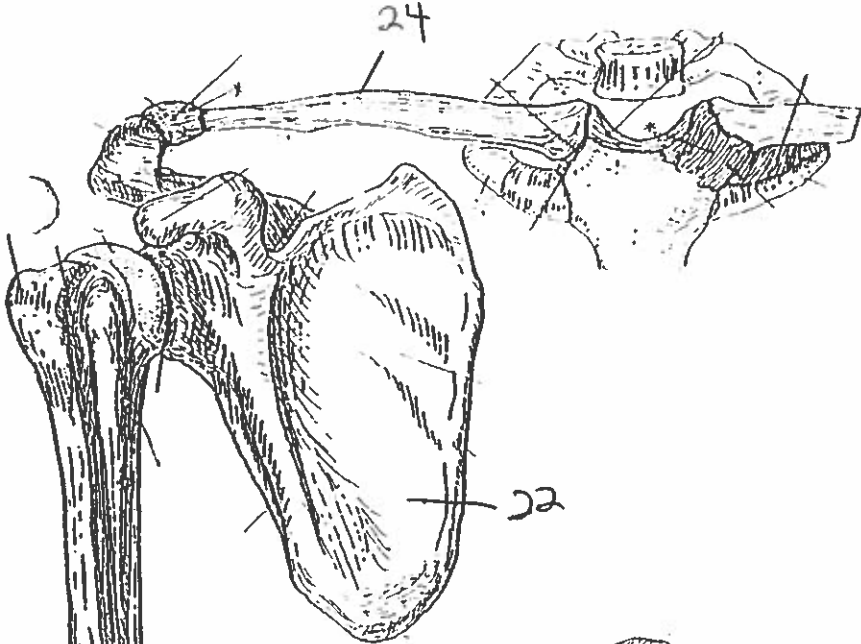
SUPERIOR VIEW



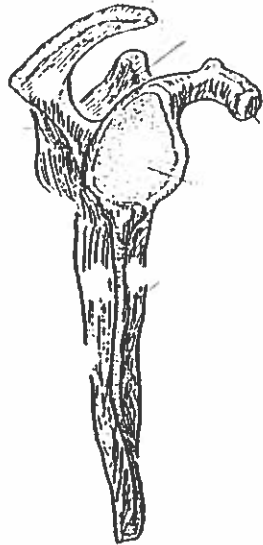
POSTERIOR VIEW

# BONY THORAX

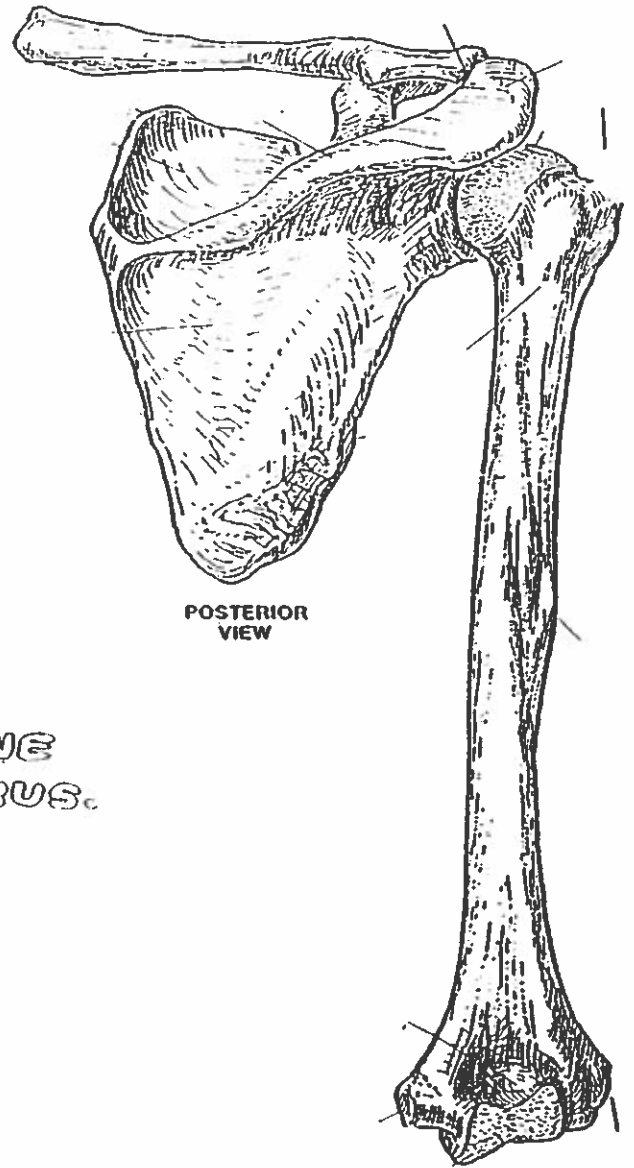




ANTERIOR VIEW  
(Right arm)



LATERAL VIEW

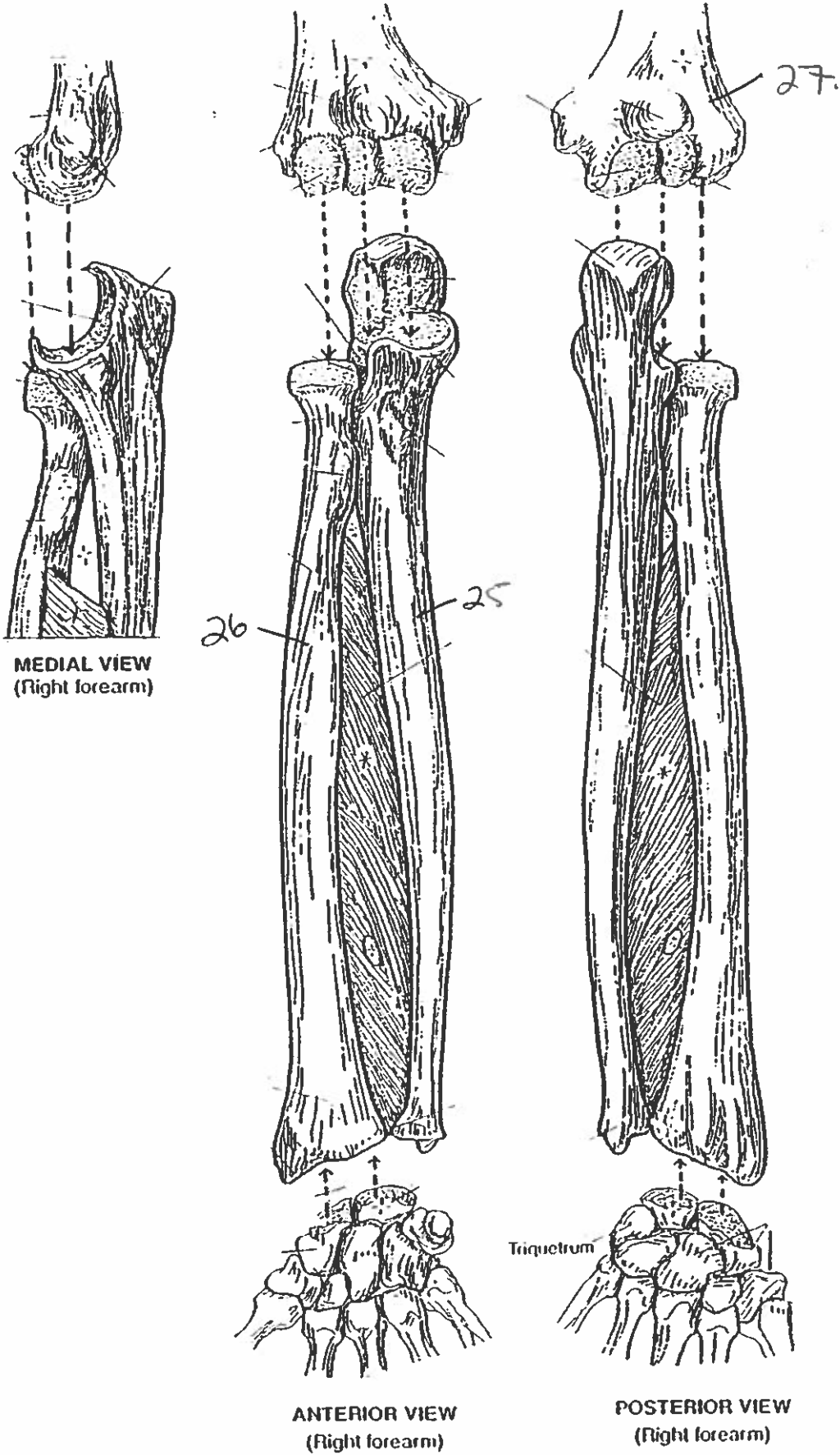


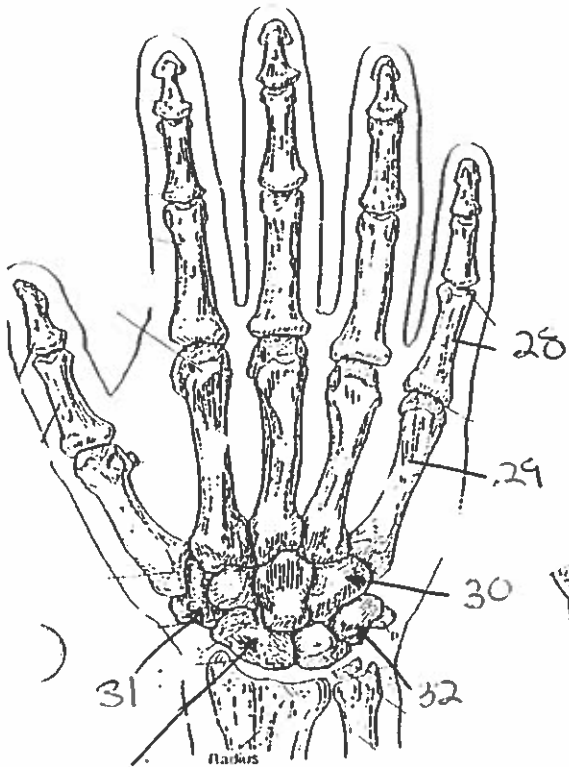
POSTERIOR VIEW

PECTORAL GIRDLE & ARM BONE  
HUMERUS.

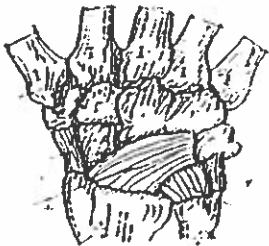
23

# FOREARM BONES

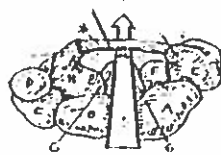




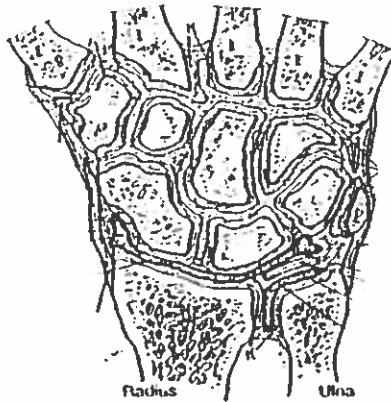
POSTERIOR (DORSAL) VIEW  
(right hand)



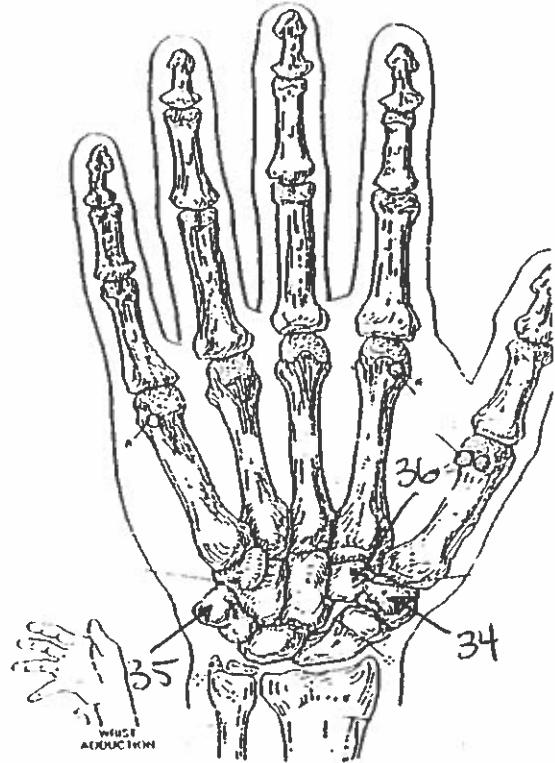
MAJOR LIGAMENTS



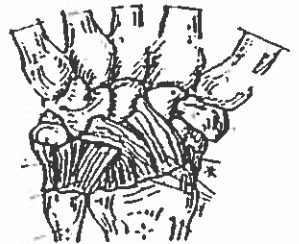
CARPAL TUNNEL



JOINTS OF WRIST & CARPALS  
(Dorsal view of frontal section)

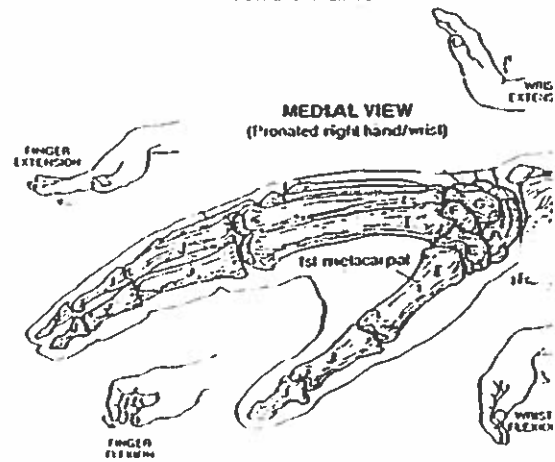


ANTERIOR (PALMAR) VIEW  
(right hand)



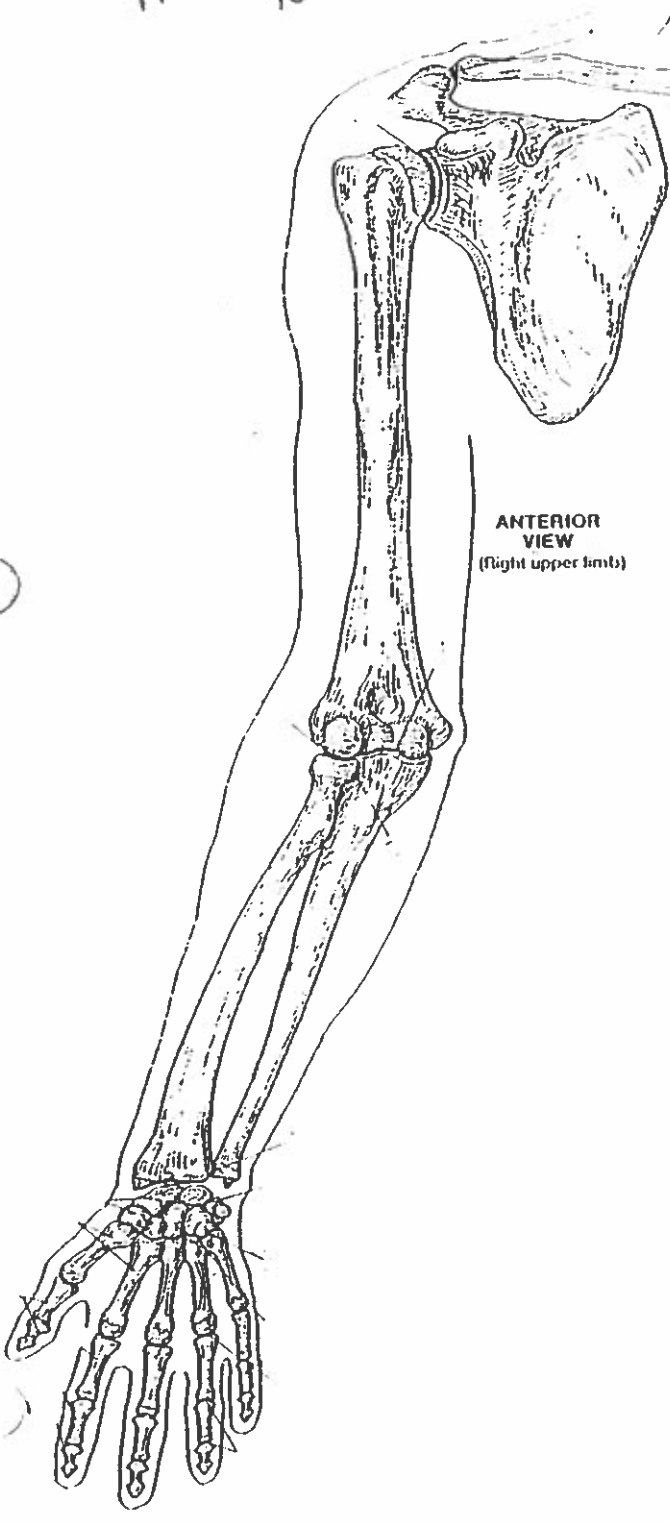
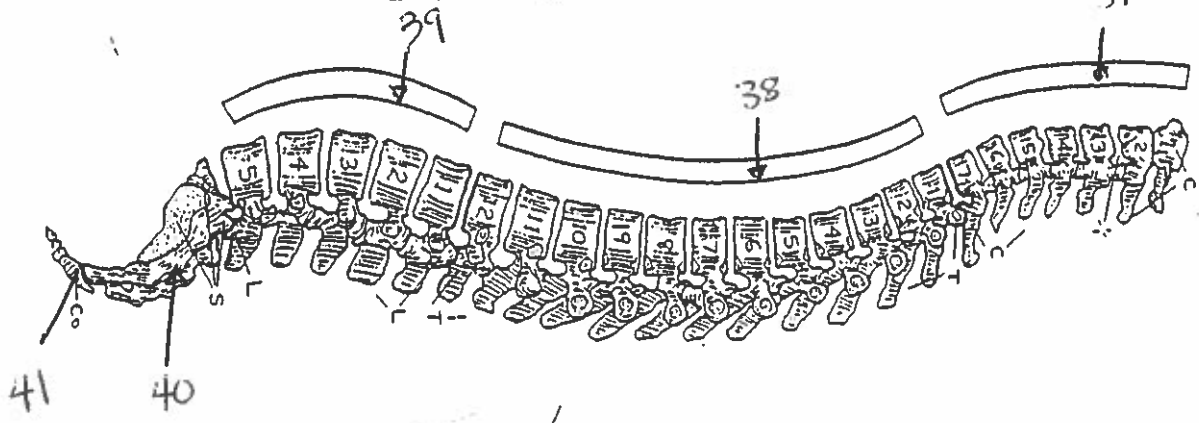
MAJOR LIGAMENTS

## WRIST AND HAND BONES

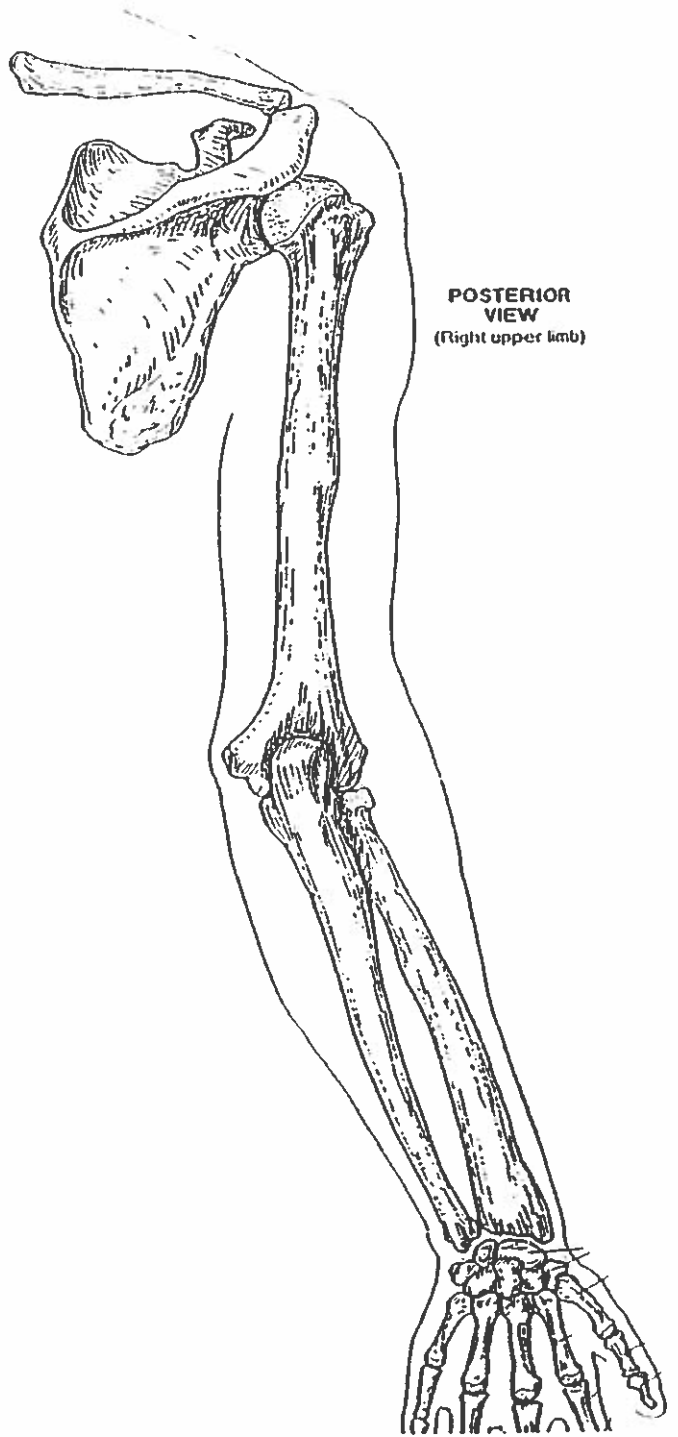


MEDIAL VIEW  
(Pronated right hand/wrist)

# VERTEBRAL COLUMN



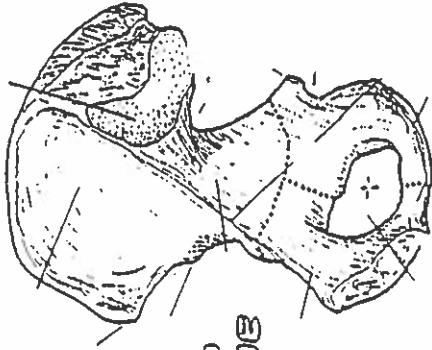
ANTERIOR VIEW  
(Right upper limb)



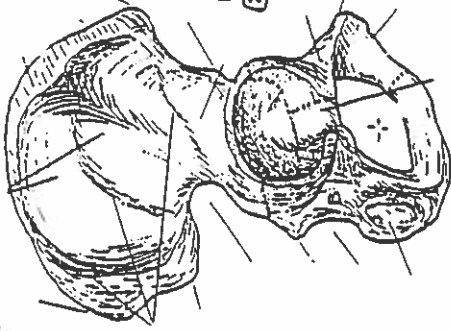
POSTERIOR VIEW  
(Right upper limb)

# HIP BONE, PELVIC GIRDLE, & PELVIS

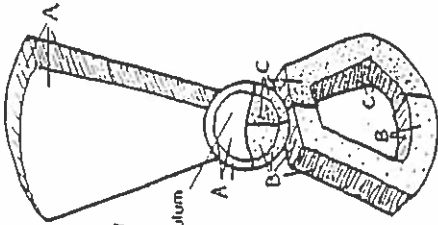
MEDIAL VIEW  
(Right bone)



LATERAL VIEW  
(Right bone)



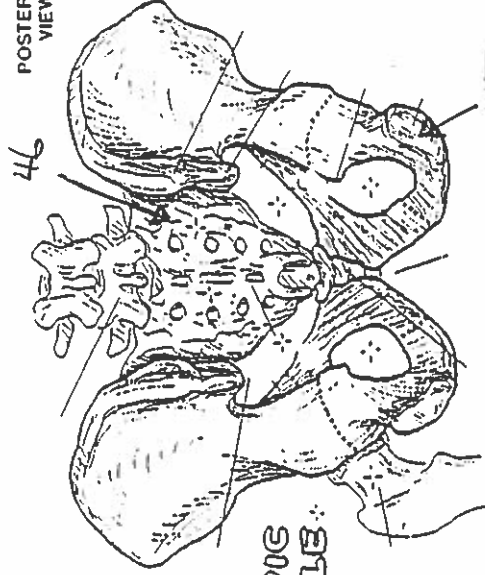
HIP BONE



LATERAL VIEW  
(Diagrammatic)

Acetabulum

POSTERIOR VIEW

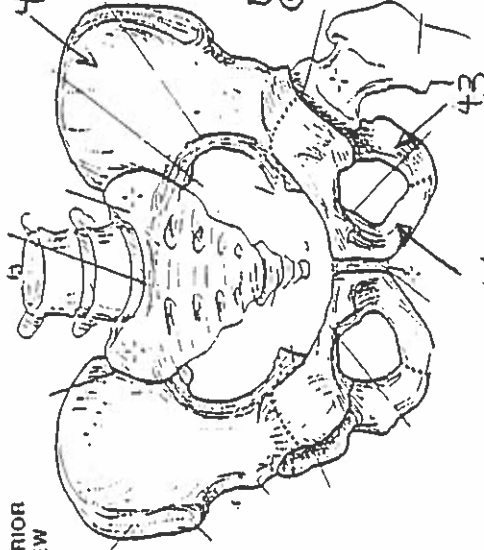


46

45

PELVIC GIRDLE

ANTERIOR VIEW

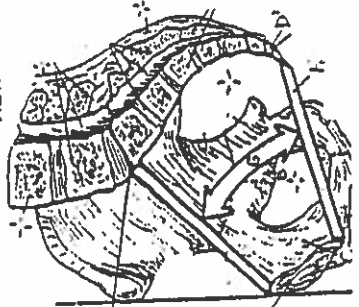


ANTERIOR VIEW

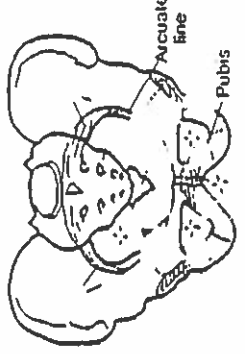
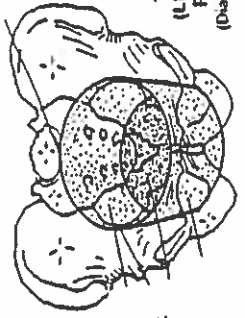
42

47

MEDIAL/SAGITTAL VIEW

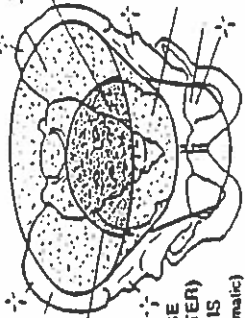


TRUE (LESSER) PELVIS  
(Diagrammatic)

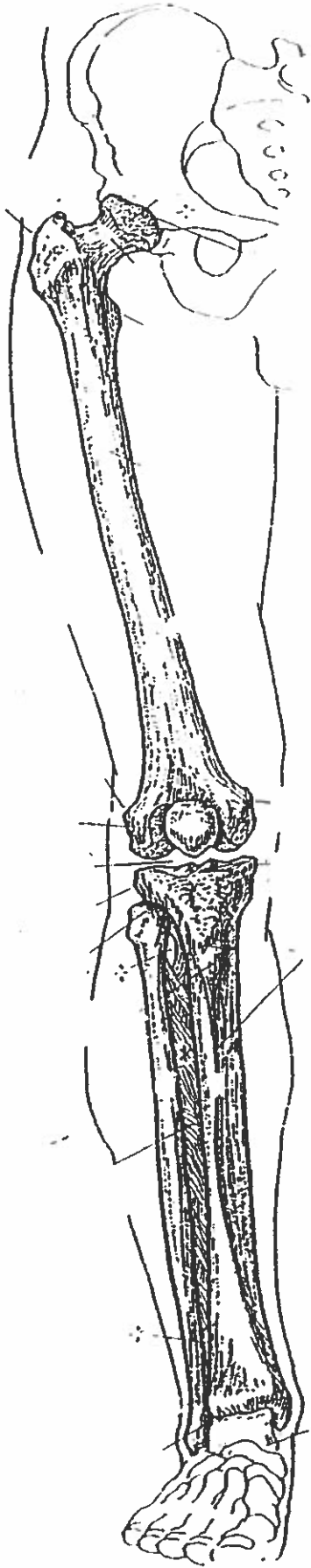


PELVIS

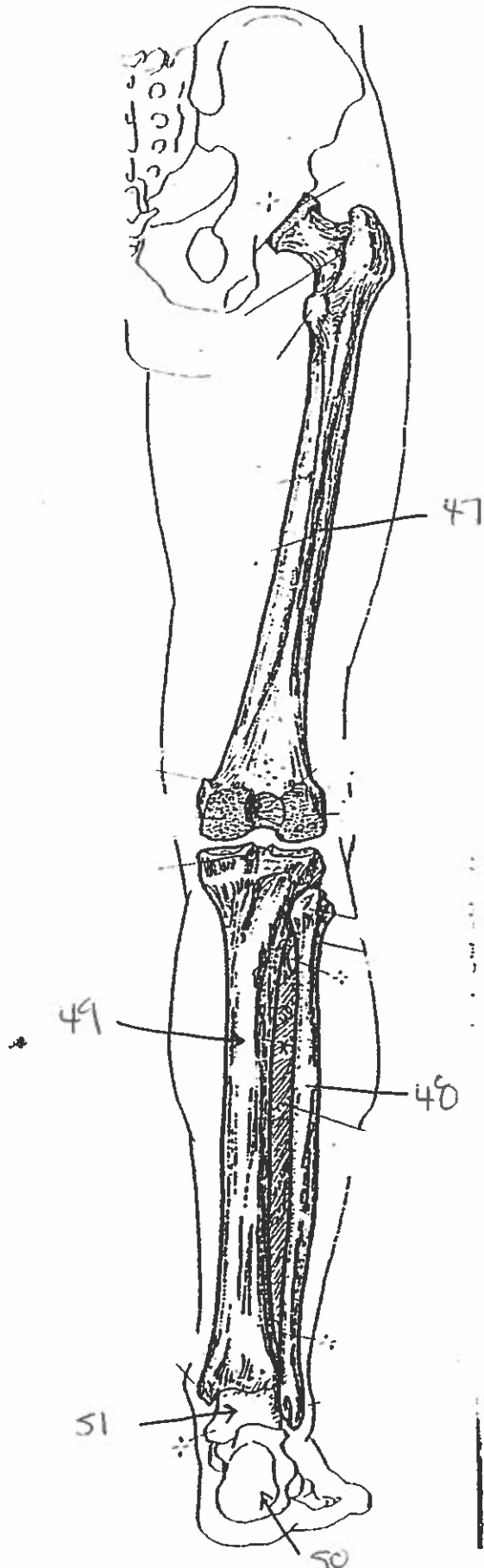
FALSE (GREATER) PELVIS  
(Diagrammatic)



ANTERIOR VIEW  
(Right limb)



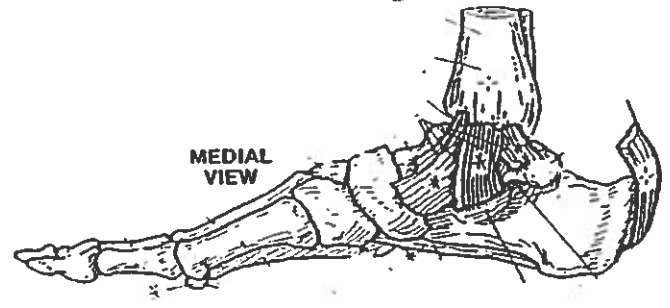
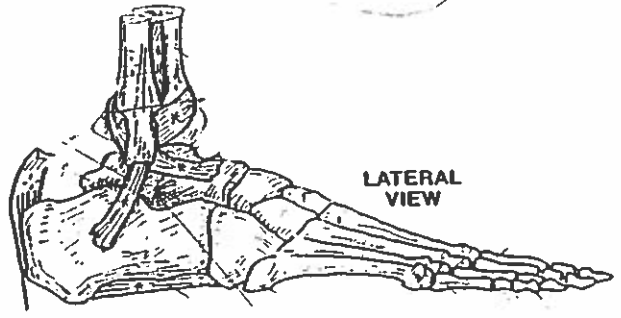
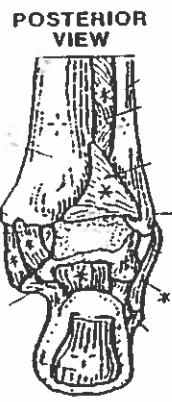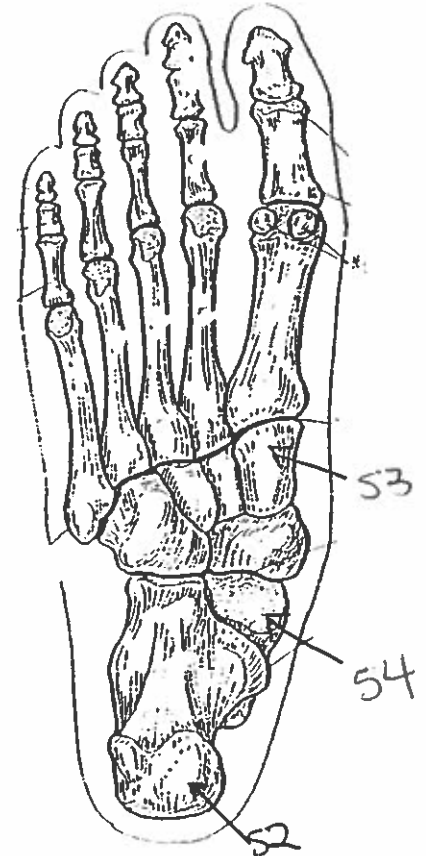
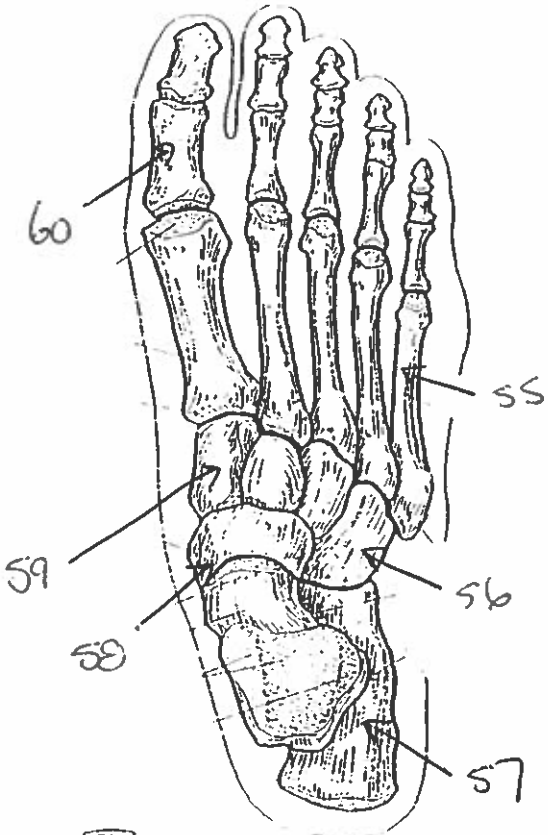
POSTERIOR VIEW  
(Right limb)



THIGH & LEG BONES



# ANKLE & FOOT BONES



# All Bones:

1. frontal
2. parietal
3. temporal
4. parietal
5. maxilla
6. mandible.
7. parietal
8. temporal
9. occipital
10. maxilla
11. parietal
12. parietal
13. temporal
14. mandible.
15. manubrium
16. body
17. true rib
18. false rib
19. floating rib
20. atlas
21. clavicle
22. scapula
23. humerus
24. clavicle.
25. ulna
26. radius
27. humerus
28. phalanges
29. metacarpals
30. hamate

31. trapezium
32. triquetrum
33. scaphoid.
34. trapezium
35. pisiform
36. trapezoid.
37. cervical vertebra
38. Thoracic vertebra
39. lumbar vertebra
40. sacrum
41. coccygeal/coccyx.
42. ilium
43. ischium
44. pubis
45. ischium
46. sacrum
47. femur
48. tibia ↵
49. fibula ↵
50. calcaneus
51. talus
52. calcaneus
53. cuneiform
54. talus
55. metatarsal
56. cuboid
57. calcaneus
58. navicular
59. cuneiform
60. phalange