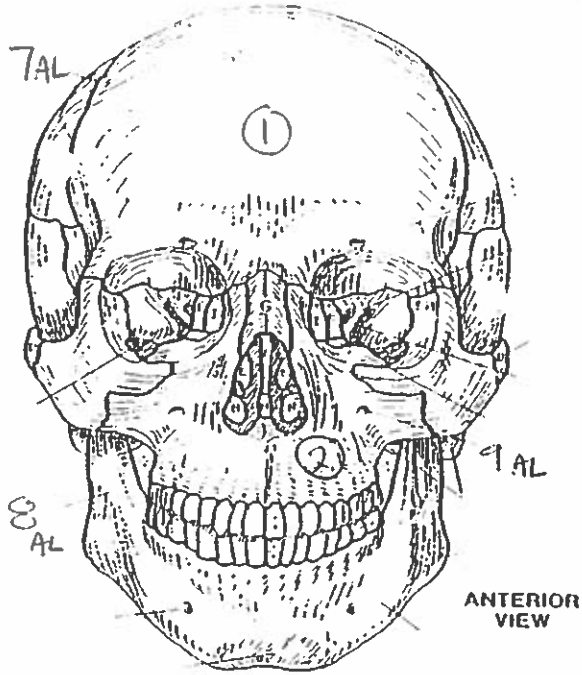
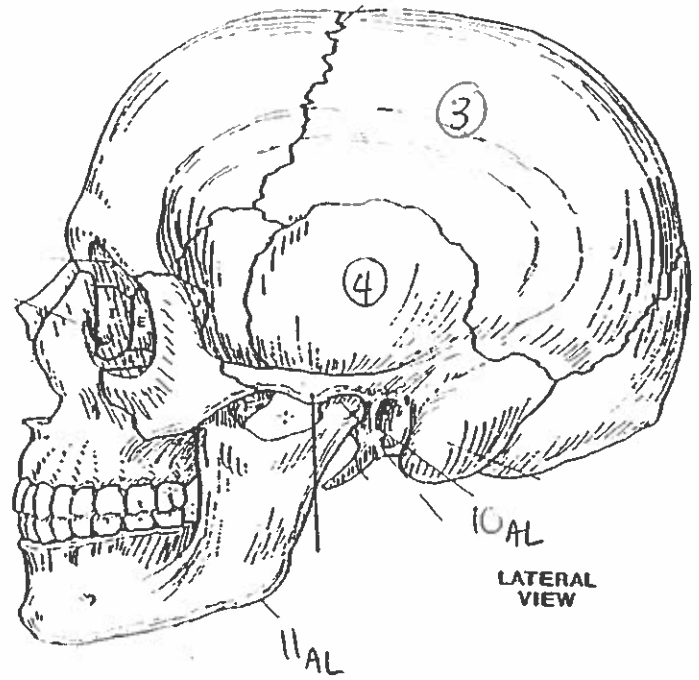


Quiz #5: All Bones & Landmarks

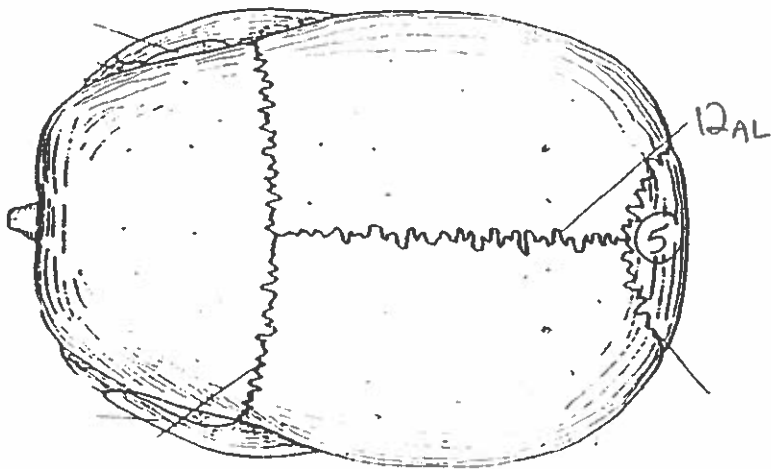
BONES OF THE SKULL.



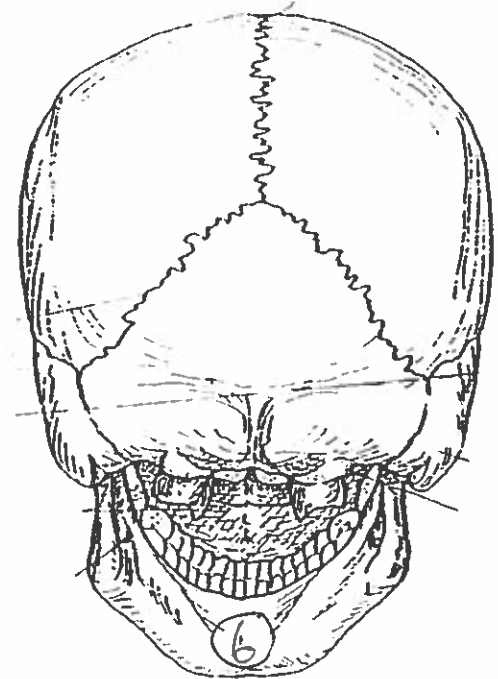
ANTERIOR VIEW



LATERAL VIEW

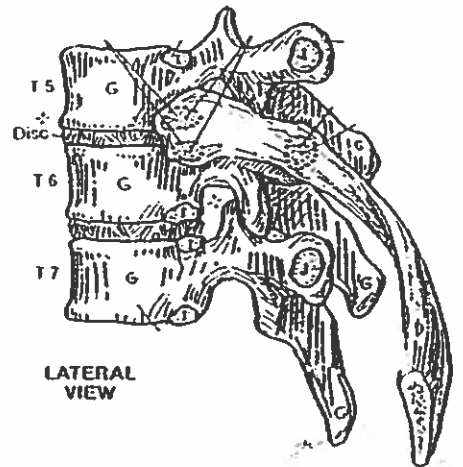
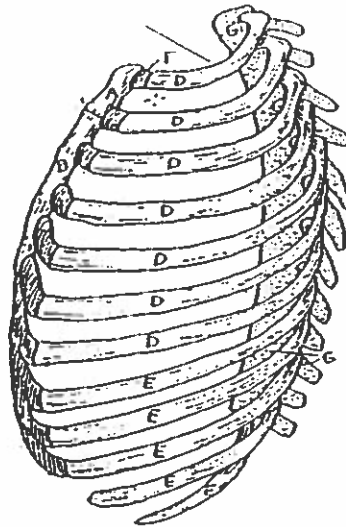

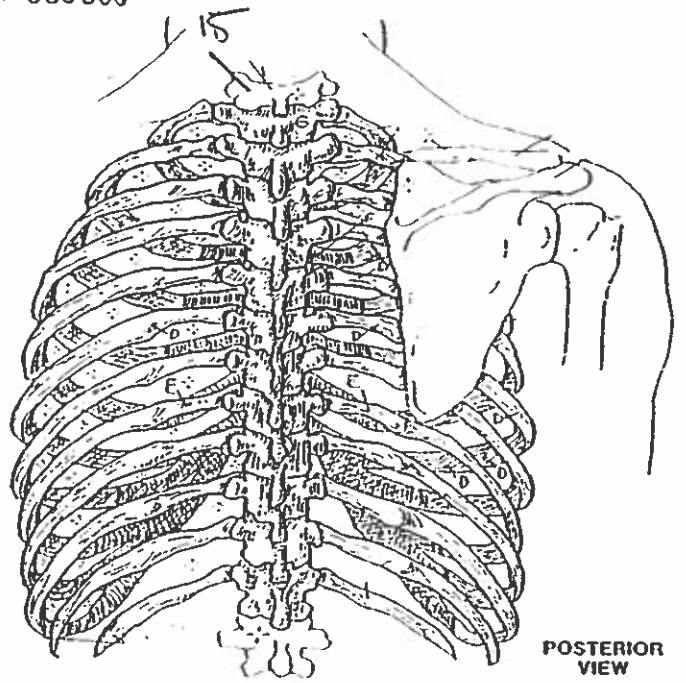
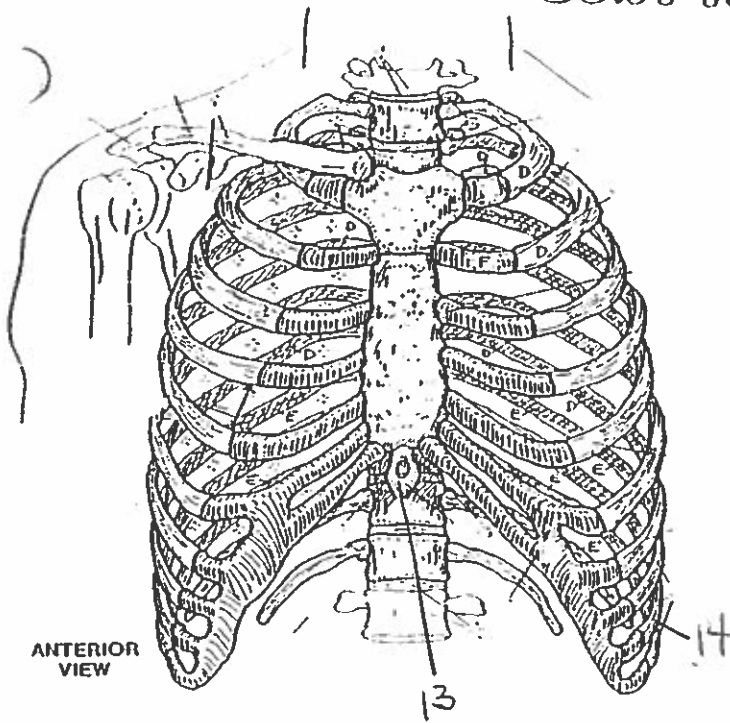


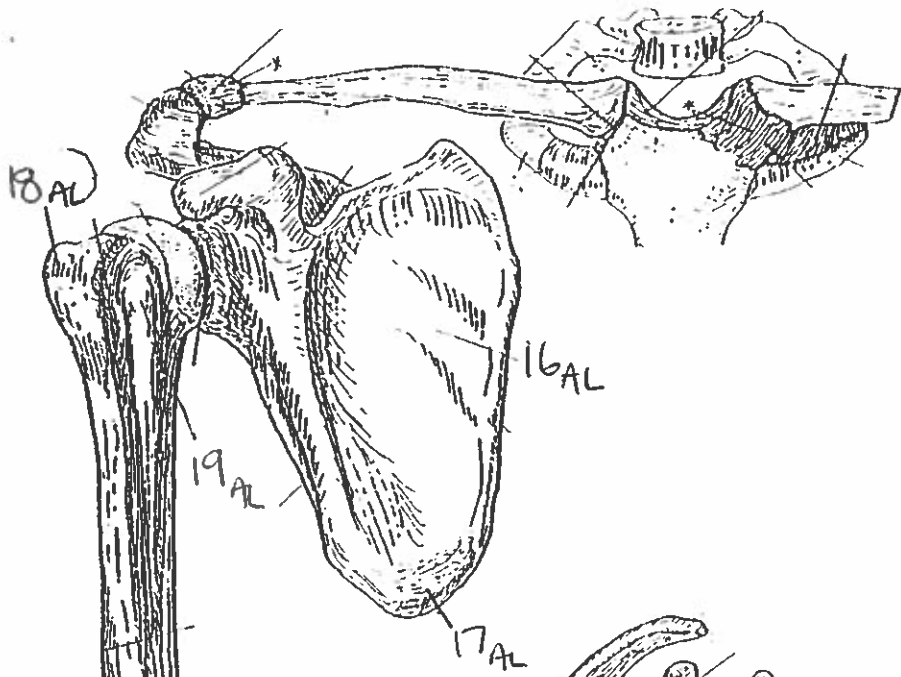
SUPERIOR VIEW



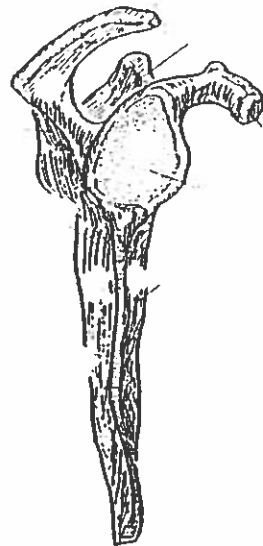
POSTERIOR VIEW

# BONY THORAX

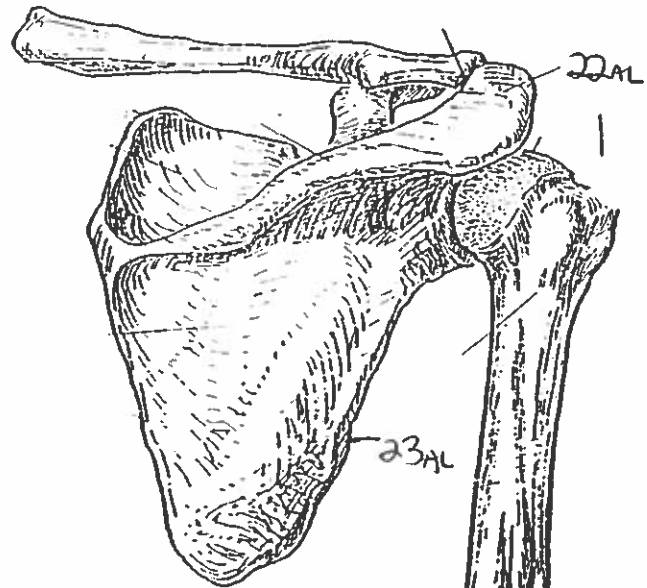




ANTERIOR VIEW  
(right arm)



LATERAL VIEW



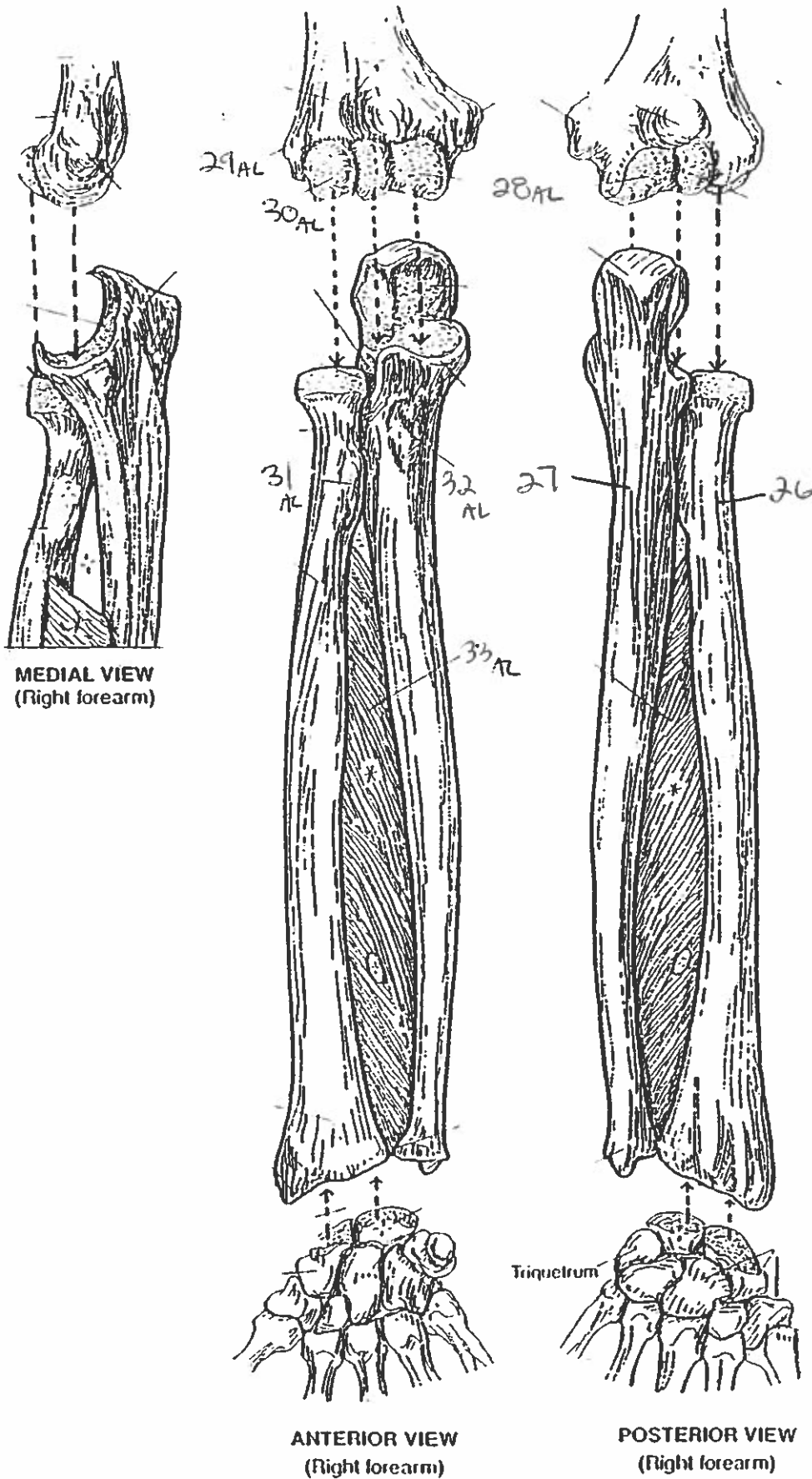
POSTERIOR VIEW

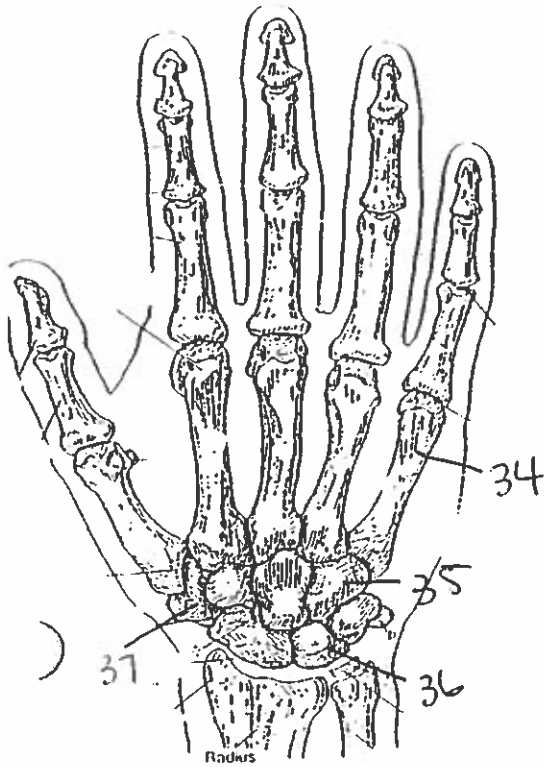
PECTORAL GIRDLE & ARM BONE  
HUMERUS.

24AL

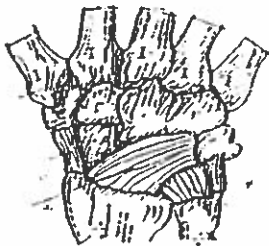
25AL

# FOREARM BONES

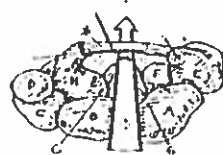




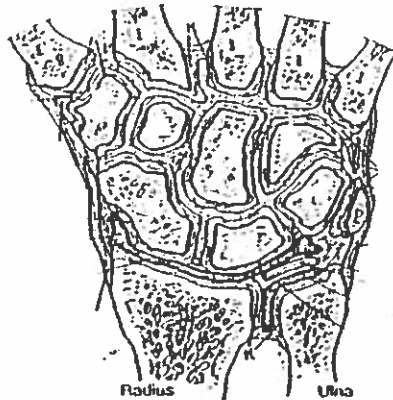
POSTERIOR (DORSAL) VIEW  
(Right hand)



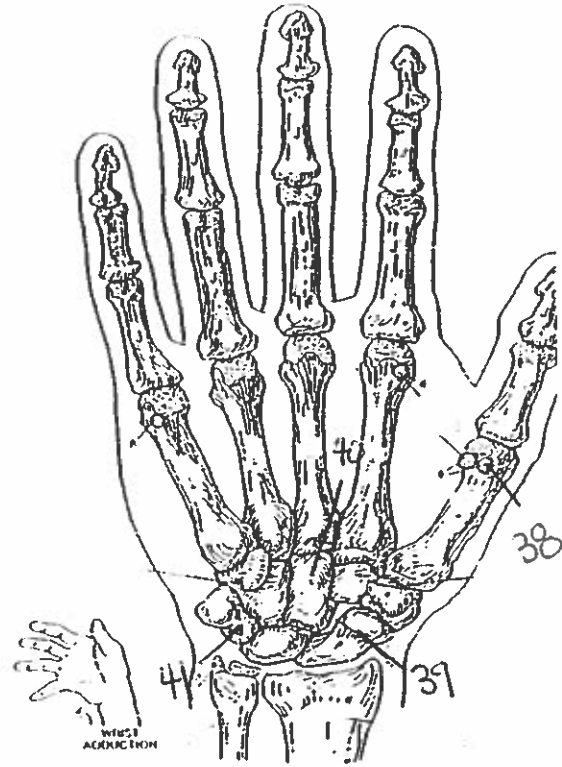
MAJOR LIGAMENTS



CARPAL TUNNEL



JOINTS OF WRIST & CARPALS  
(Dorsal view of frontal section)

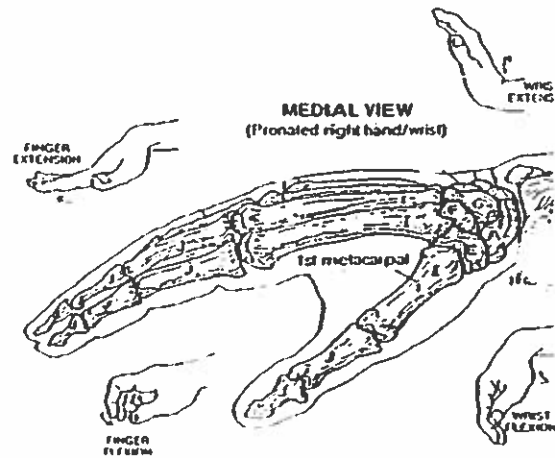


ANTERIOR (PALMAR) VIEW  
(Right hand)



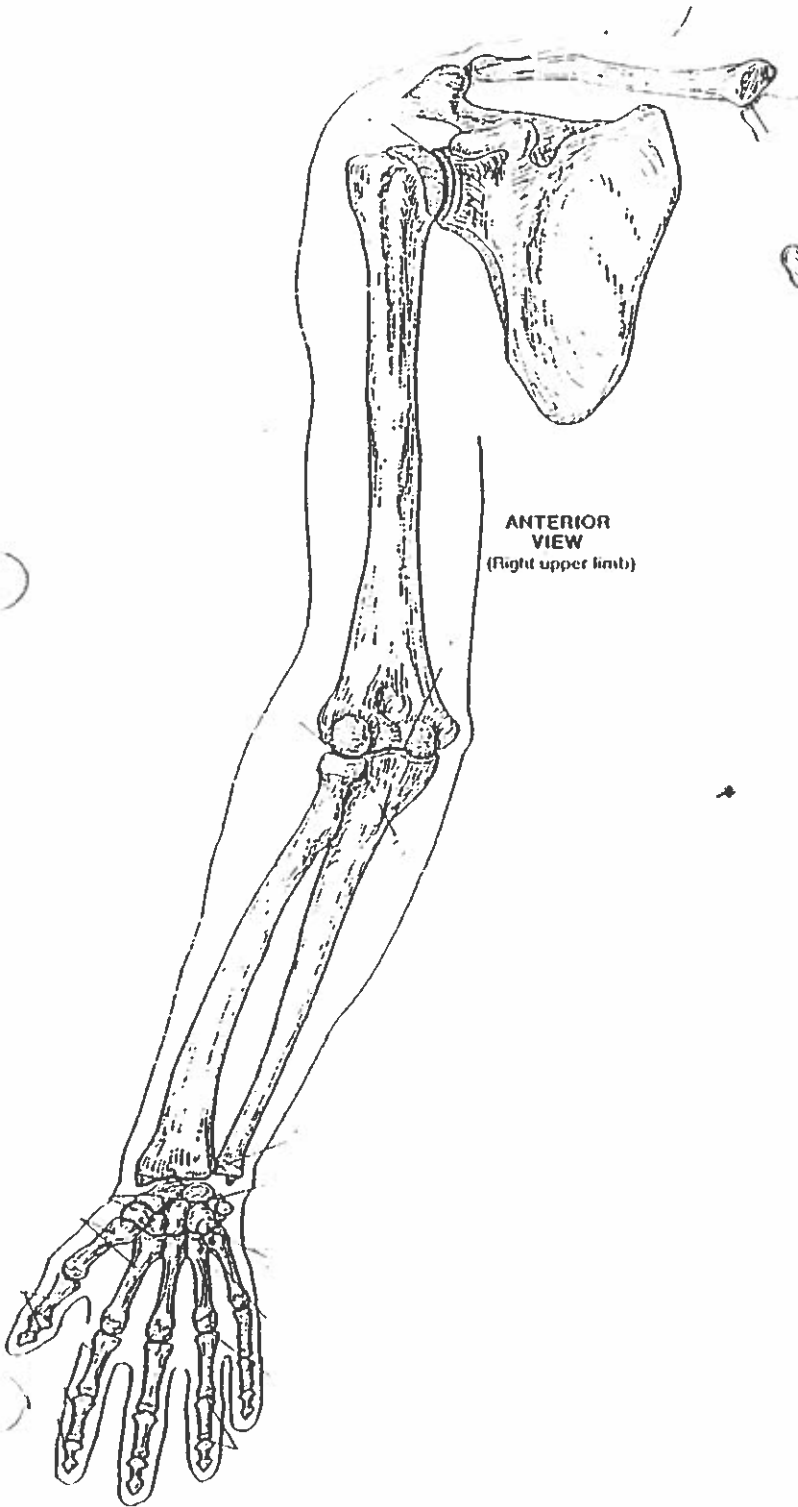
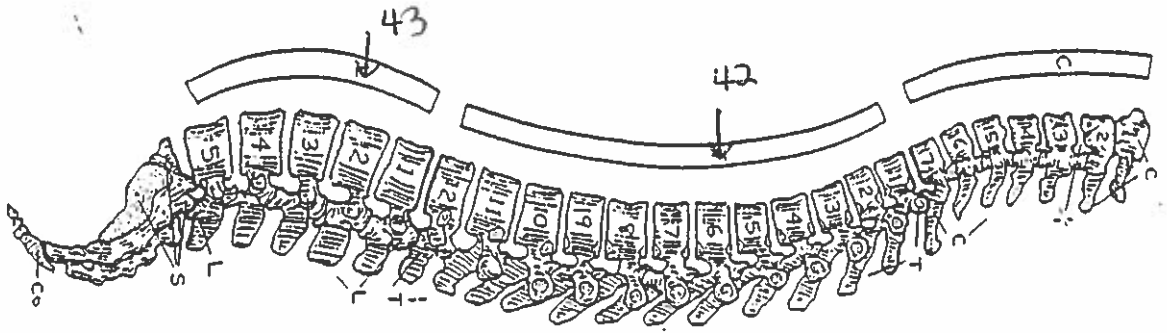
MAJOR LIGAMENTS

## WRIST AND HAND BONES

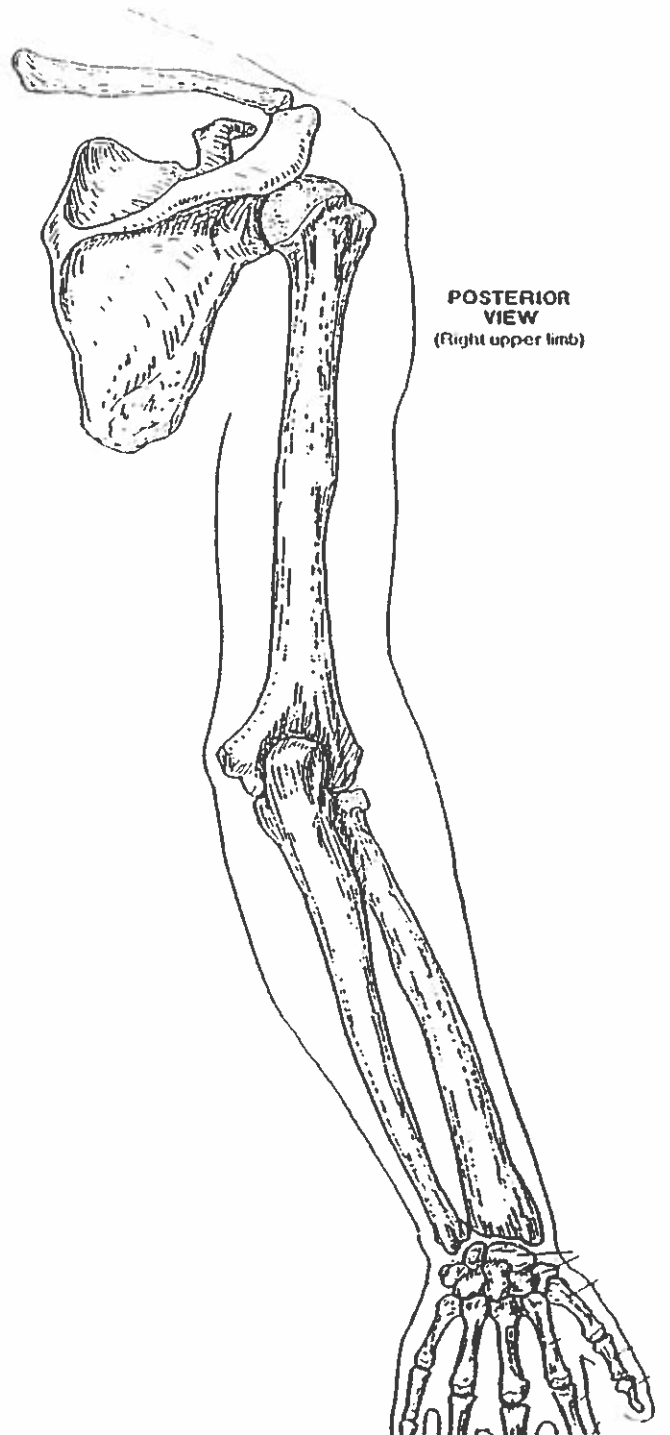


MEDIAL VIEW  
(Pronated right hand/wrist)

# VERTEBRAL COLUMN



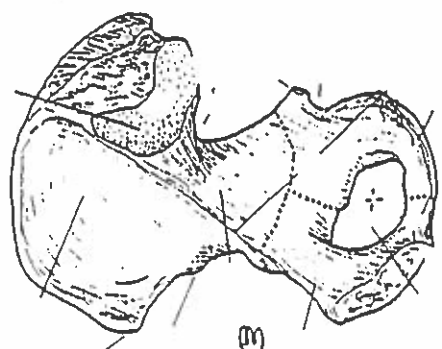
**ANTERIOR VIEW**  
(Right upper limb)



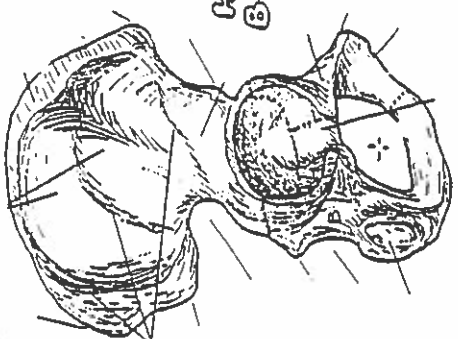
**POSTERIOR VIEW**  
(Right upper limb)

# HIP BONE, PELVIC GIRDLE, & PELVIS

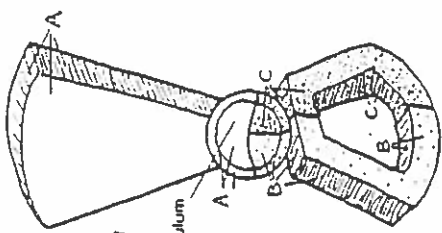
MEDIAL VIEW  
(Right bone)



LATERAL VIEW  
(Right bone)



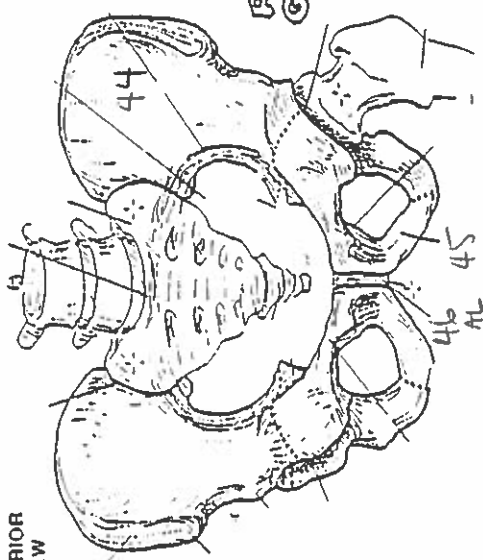
HIP BONE



LATERAL VIEW  
(Diagrammatic)

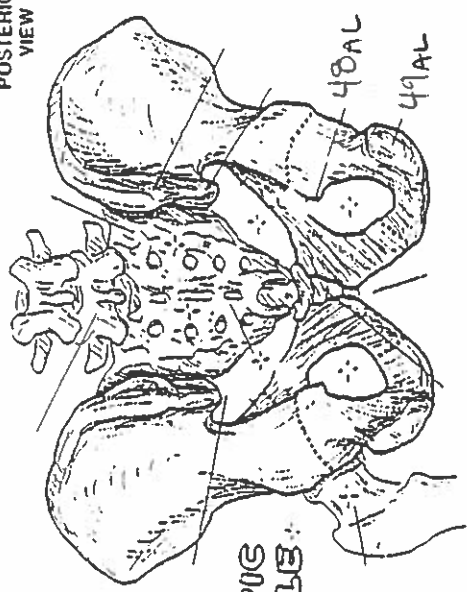
Acetabulum

ANTERIOR VIEW

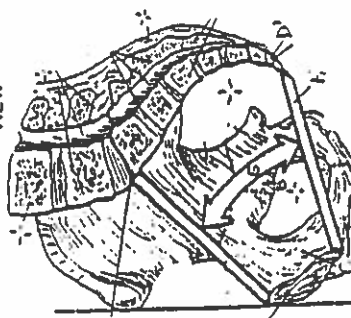


PELVIC GIRDLE

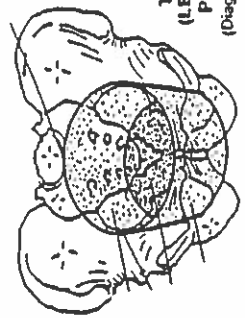
POSTERIOR VIEW



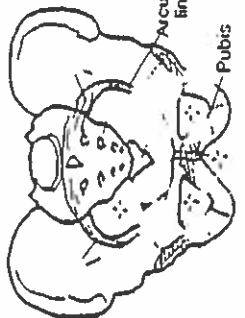
MEDIAL/SAGITTAL VIEW



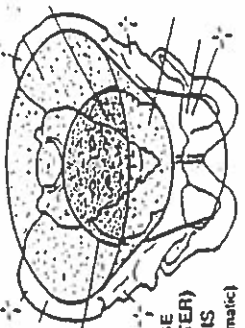
TRUE (LESSER) PELVIS  
(Diagrammatic)



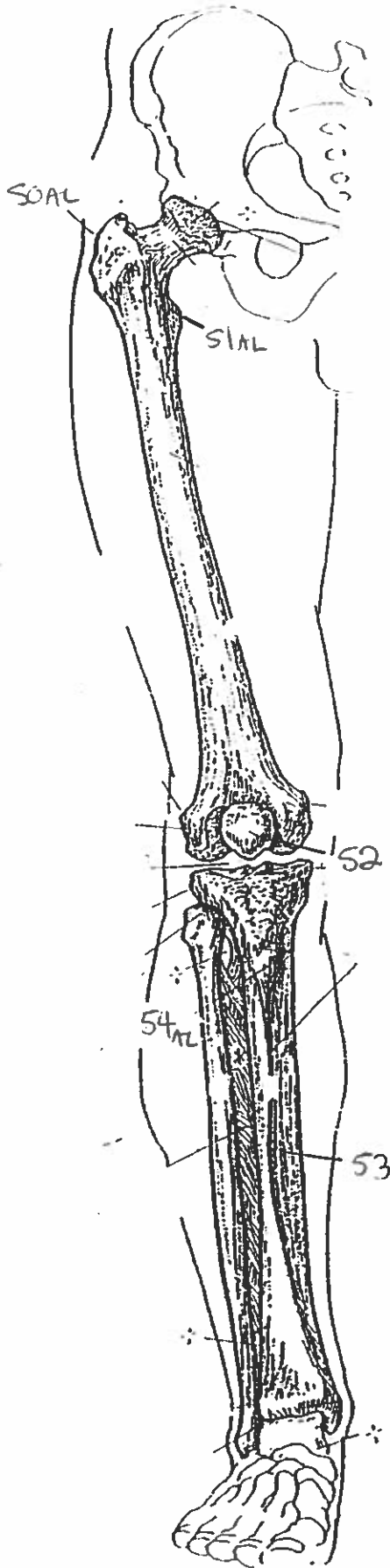
Acetabulum  
Pubis



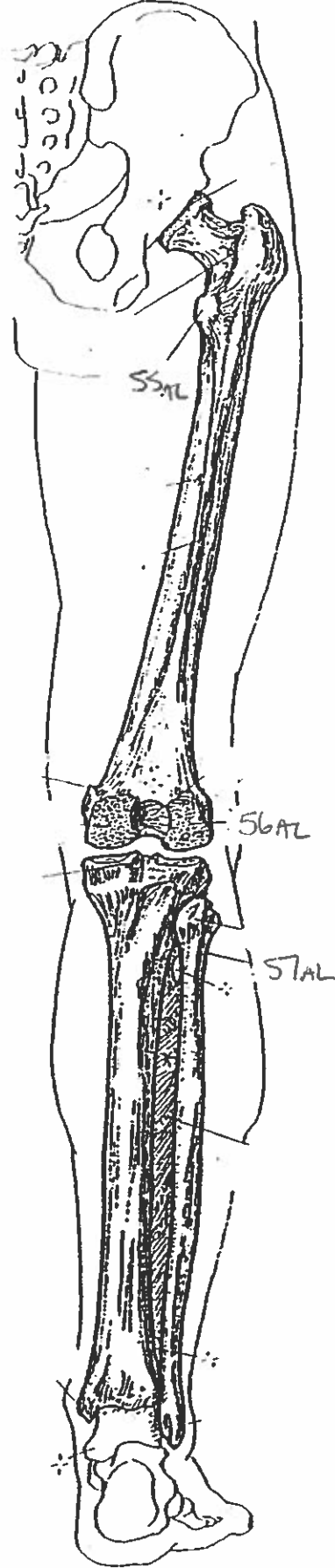
FALSE (GREATER) PELVIS  
(Diagrammatic)



ANTERIOR VIEW  
(Right limb)



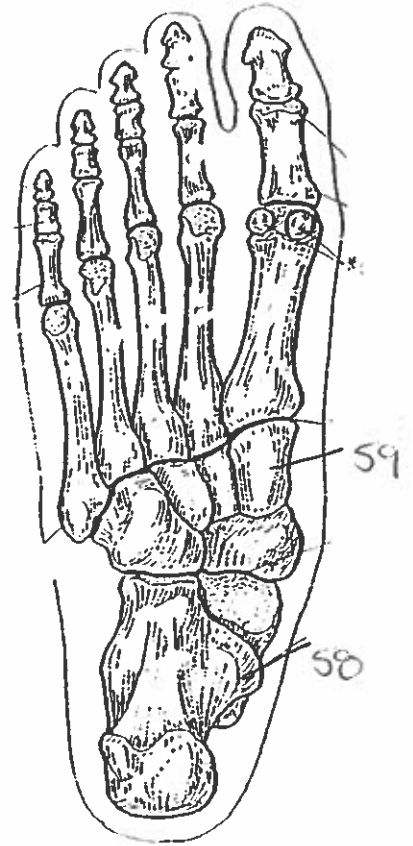
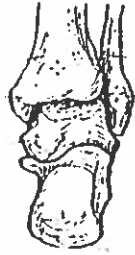
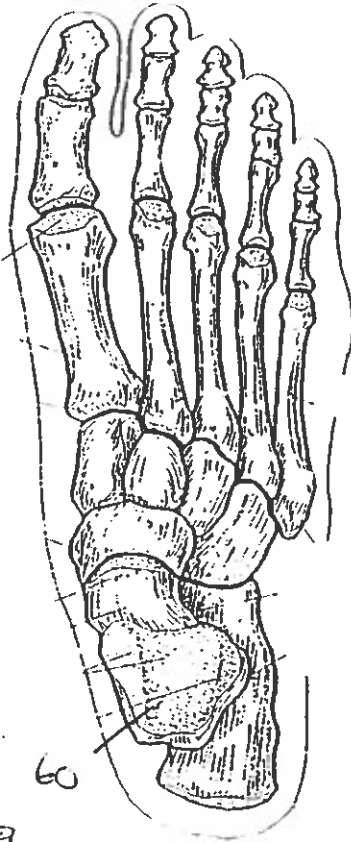
POSTERIOR VIEW  
(Right limb)



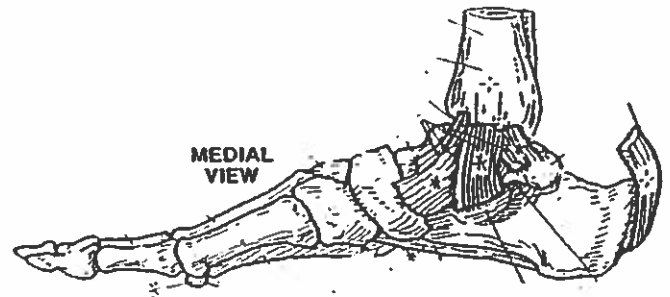
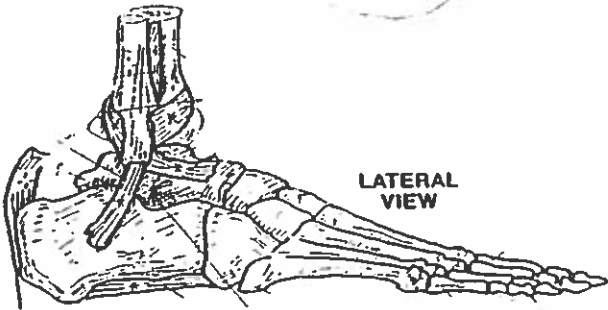
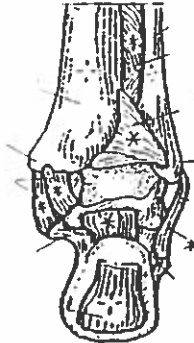
THIGH & LEG BONES



# ANKLE & FOOT BONES



POSTERIOR VIEW



## Quiz #5 All bones & landmarks.

1. frontal bone
2. maxilla bone
3. parietal bone
4. temporal bone
5. occipital bone
6. mandible bone
7. coronal suture
8. ramus
9. infraorbital foramen
10. external auditory meatus
11. angle
12. sagittal suture
13. xiphoid process
14. false ribs
15. atlas
16. subscapular fossa
17. inferior angle
18. greater tubercle
19. lesser tubercle
20. coronoid fossa
21. capitulum
22. acromion
23. lateral margin
24. olecranon fossa
25. trochlea.
26. radius bone
27. ulna bone
28. trochlea
29. lateral epicondyle.
30. capitulum

31. radial tuberosity.
32. ulna tuberosity.
33. interosseous membrane.
34. metacarpal bone
35. hamate
36. lunate
37. trapezium
38. sesamoid
39. scaphoid
40. capitate
41. triquetrum
42. thoracic ~~thoracic~~ vertebra
43. lumbar vertebra
44. ilium bone
45. pubis bone
46. symphysis pubis
47. iliac crest
48. ischial spine
49. ischial tuberosity
50. greater trochanter
51. lesser trochanter
52. patella
53. tibia
54. tibial tuberosity.
55. lesser trochanter
56. lateral condyle
57. neck
58. calcaneus
59. cuneiform
60. talus.